

# Pathological findings in common foxes suffering from cardiorespiratory syndrome

AGNIESZKA NOSZCZYK-NOWAK<sup>1</sup>, IZABELA JANUS<sup>2</sup>, TOMASZ PIASECKI<sup>3</sup>

<sup>1</sup>Department of Internal and Diseases with Clinic for Horses, Dogs and Cats, Faculty of Veterinary Medicine, Wrocław University of Environmental and Life Sciences, Grunwaldzki Sq. 47, 50-366 Wrocław, Poland

<sup>2</sup>Department of Epizootiology with Clinic of Birds and Exotic Animals, Faculty of Veterinary Medicine, Wrocław University of Environmental and Life Sciences, Grunwaldzki Sq. 45, 50-360 Wrocław, Poland

<sup>3</sup>Department of Pathology, Faculty of Veterinary Medicine, Wrocław University of Environmental and Life Sciences, C.K. Norwida Str. 31, 50-375 Wrocław, Poland

Received 25.03.2021

Accepted 06.05.2021

Noszczyk-Nowak A., Janus I., Piasecki T.

## Pathological findings in common foxes suffering from cardiorespiratory syndrome

### Summary

Cardiorespiratory syndrome of common foxes has been reported since the 1980s. Although the condition is observed at a number of farms in Europe and America, its etiology still remains elusive. The study was conducted at a common fox (*Vulpes vulpes*) farm located in Central Poland, having a total of 500 females and 150 males and an average yearly production of 1,900 cubs. Deaths due to cardiorespiratory syndrome were recorded at the farm in 2012 and 2013, corresponding to 5.32% and 2.14% new young mortality rates, respectively. Postmortem examination included 38 foxes that died in 2013, as well as 12 hearts collected from foxes that died in 2012. Gross pathological findings documented in the examined material were generally typical for the cardiorespiratory syndrome of foxes. However, detailed pathological examination of the hearts revealed a dilatation of the right atrioventricular opening and abnormal structure of the tricuspid valve in all cases. The septal cusp was shortened, thickened, and immobilized due to fusion with the interventricular septum. The fact that tricuspid valve dysplasia was observed on postmortem examination of all animals that died with the symptoms of cardiorespiratory syndrome confirms a potential involvement of congenital heart defects in the etiology of this condition.

**Keywords:** atrioventricular valve dysplasia, cardiorespiratory syndrome, common fox, lung-heart syndrome, tricuspid valve, mitral valve, heart defect, pathology

Cardiorespiratory syndrome (also called lung-heart syndrome) among common foxes was described for the first time in mid 1980s in Poland and Canada and has been reported as a cause of significant losses in fox farms (3, 9). However, despite extensive research, the etiology of the disease still remains elusive. Usually, the disease affects young, 2- to 6-month-old, animals. The most characteristic clinical symptom of the cardiorespiratory syndrome in foxes is severe dyspnea; furthermore, the animals present with increased heart rate and complete loss of appetite. Elevating the fox and holding it by the tail with head down causes massive foamy bloody nasal discharge, exacerbation of dyspnea and even death. The symptoms are present suddenly and persist for several hours to several days. Eventually, the animal dies with the symptoms of exacerbating dyspnea, and sometimes also progressive cachexia. Postmortem examination usually reveals variable volume of fluid

in pleural and pericardial cavities and an enlargement of the heart. Also pulmonary edema can be observed, sometimes with signs of pneumonia. Moreover, some authors documented pathological changes corresponding to dilated cardiomyopathy (6). Motz et al. (7) observed typical signs of hypoxia on histopathological examination of the myocardial specimens; only few specimens showed discrete infiltration with mononuclear cells. Based on the results of many studies, the involvement of infectious factors in etiopathogenesis of the cardiorespiratory syndrome can be virtually excluded (2, 11, 14, 15). Also the role of taurine deficiency was studied extensively, as involvement of this amino acid in the etiopathogenesis of cardiorespiratory syndrome was suspected, similarly as in the case of feline cardiomyopathy. However, this hypothesis was not confirmed experimentally; moreover, administration of taurine did not influence the therapeutic outcomes of the

cardiorespiratory syndrome (3, 12). Our previous study conducted on foxes without signs of cardiorespiratory syndrome revealed that over half of the animals from three farms in Poland had valve dysplasia (8).

The aim of the study was to examine the frequency of heart valve dysplasia among foxes dying with symptoms of cardiorespiratory syndrome to evaluate its role in the pathogenesis of the disease.

### Material and methods

The deaths of common foxes (*Vulpes vulpes*) due to cardiorespiratory syndrome were observed during two breeding seasons (2012-2013) on a farm located in Central Poland. A total of 500 females and 150 males are kept at the farm, and the average yearly production amounts to 1900 cubs. Previously, cardiorespiratory syndrome was observed at this farm in 2002 and caused fatal outcomes in 20% of the young. In 2012, the cases of cardiorespiratory syndrome were observed between July and October; a total of 96 fatal outcomes were recorded, which corresponded to 5.32% of new young. The number of fatal outcomes due to cardiorespiratory syndrome documented in 2013 was smaller ( $n = 38$ , 2.14% of new young).

The study included 38 cadaveric specimens of foxes that died in 2013 with the typical clinical signs of cardiorespiratory syndrome, as well as 12 hearts of foxes that died in 2012, obtained during postmortem examination and frozen until analysis.

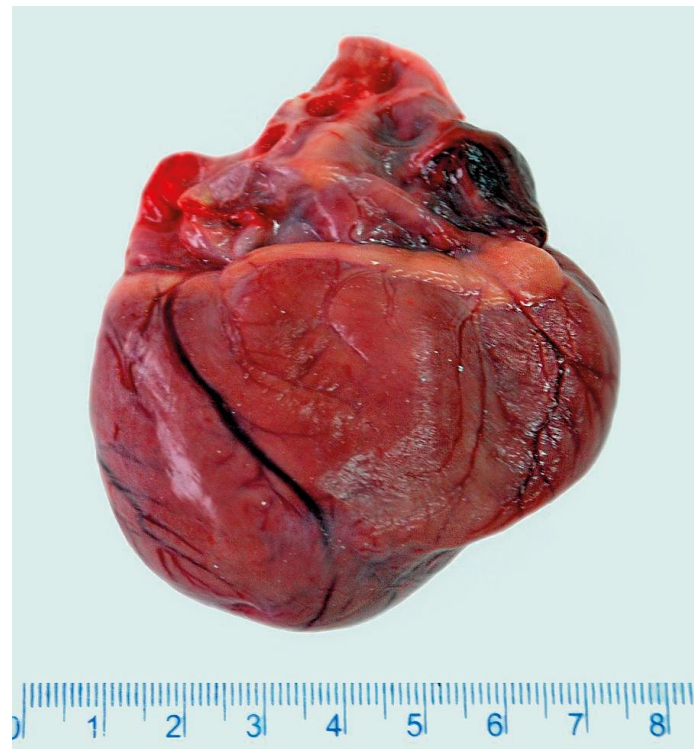
Cadavers underwent standard postmortem examination with a detailed analysis of gross pathology of the hearts (including 12 specimens from 2012). The heart examination included: (a) changes in heart shape and size, (b) analysis of ventricular internal diameter and wall thickness, (c) detailed analysis of the morphology of mitral and tricuspid valve, papillary muscles and tendinous chords.

Myocardial sections were fixed for 24 hours in 7% buffered formaldehyde, processed routinely, embedded in paraffin and cut into 4  $\mu\text{m}$ -thick slices. Microscopic slides were stained with hematoxylin and eosin and subjected to histopathological examination. The examination included: morphology of cardiomyocyte (presence of absence of signs of cardiomyocyte and nuclei degeneration), amount of interstitial tissue and presence of inflammatory infiltrates. Microphotographs of the sections were subjected to a computer image analysis on a computer connected to Olympus BX53 light microscope equipped with ColorView IIIu digital camera (Olympus, Japan). The digital analysis was conducted with cell^A software (Olympus Soft Imaging Solution GmbH, Germany).

According to the Polish law studies conducted on animal tissue (including organs collected post-mortem) do not require permission from the Ethical Board.

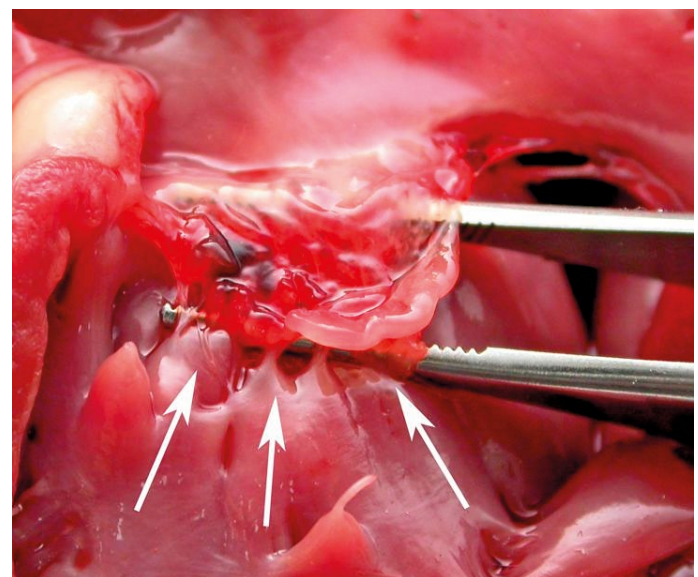
### Results and discussion

The postmortem examination of foxes that died in 2013 revealed pulmonary congestion and edema, and the presence of foamy bloody fluid in large bronchi and trachea. Additionally, 20-140 ml of straw-yellow or straw-bloody fluid were revealed in pleural cavities of 35 (92.1%) of the foxes. Moreover, 17 animals (44.7%) had fluid in the pericardium, and 11 (28.9%) in the abdominal cavity.

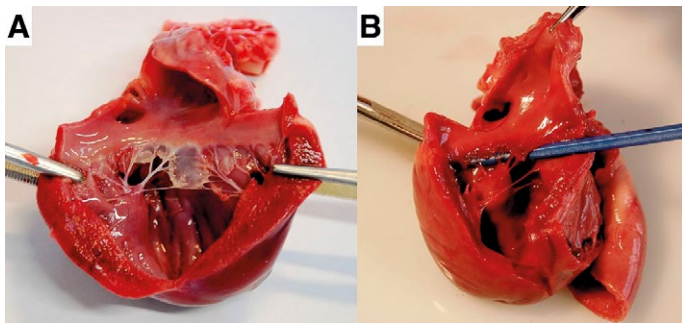


**Fig. 1. Gross examination of the heart. The heart is round-shaped with a visible enlargement of the left and right ventricle**

The hearts of all the animals were round-shaped and enlarged (Fig. 1), mostly due to dilatation of the right ventricle and right atrium. The lumen of the right ventricle was enlarged (up to 6.5 cm in diameter below the tricuspid valve fibrous ring), and its wall was thinned down to 2 mm. Moreover, a dilatation of the right atrio-ventricular opening and abnormal structure of the tricuspid valve were documented in all cases. The septal cusp was shortened, thickened, and immobilized due to fusion with the interventricular septum (Fig. 2). The tendinous chords of the septal cusp were completely absent in 29



**Fig. 2. Gross examination of tricuspid valve. The septal cusp is shortened, thickened, and immobilized due to fusion with the interventricular septum**



**Fig. 3.** Gross examination of the mitral valve. **A.** The tendinous chords of thicker posterior cusp are significantly shortened and thickened. **B.** Thickened and dysplastic posterior cusp with shortened tendinous chords

specimens (58%), or significantly shortened in another 21 cases (42%). The number of papillary muscles in the right ventricle varied between 2 and 4.

Moreover, an abnormal structure of the mitral valve was documented in 16 animals (32%). The posterior cusp was thick and abnormally shaped, and the tendinous chords were shortened, which impaired mobility of the cusp (Fig. 3). All the hearts with mitral valve abnormalities showed enlargement of the left atrium; additionally, the significant dilatation of the left ventricle ( $n = 11$ ; 22%) was observed, along with the thickening of its walls, resulting probably from the secondary stenosis of the atrioventricular opening, due to structural abnormalities of the mitral valve ( $n = 6$ ; 12%).

Histopathological examination of myocardial specimens showed only a slight congestion. Morphology of cardiomyocytes, their morphometric relationships, staining, striation and amount of interstitial tissue were normal. Furthermore, no signs of inflammation, including cellular infiltration, were found in the analyzed material.

Detailed examination of the hearts of foxes that died with the signs of cardiorespiratory syndrome revealed structural alterations of the tricuspid valve in all of the cases, as well as concomitant structural defects of the mitral valve in 32% of the studied animals. The type of these defects corresponded to the characteristics of congenital tricuspid/mitral valve dysplasia that are described in other animal species and in humans, and may cause the symptoms of heart failure (4, 5, 10). The complex process of the development of the heart in the fetal period can be disturbed at many stages, which is later reflected by the morphological and/or functional abnormalities of the organ. Retinoic acid, which plays a vital role in fox nutrition and modulates various developmental stages of the heart, is listed among many potential harmful factors (1). Congenital atrioventricular valve dysplasia results from a disturbed transformation of endocardial tissue pads into valves during fetal life (13). In humans, this process starts as early as at the 4<sup>th</sup> week of gestation. Tricuspid valve dysplasia belongs to the most common congenital defects in dogs (10). An abnormal structure of one or more cusps impairs functioning of the valve, leading to its insufficiency. A concomitant atrioventricular stenosis can be observed in some cases. The presence of the defect leads to the de-

velopment of right ventricular heart failure, manifesting itself as accumulation of fluid in body cavities, dyspnea, lack of appetite, and cachexia resulting from the loss of protein (transudate); i.e. the symptoms that are also observed in the cardiorespiratory syndrome in foxes. Left ventricular overload and secondary left ventricular heart failure, typically with resultant pulmonary edema, develop at more advanced stages. Clinical manifestation of mitral valve dysplasia is predominated by the signs of left ventricular heart failure and pulmonary edema, which can progress rapidly in some cases. The clinical signs and anatomopathological lesions of cardiorespiratory syndrome among foxes, previously described by many authors (2, 3, 7, 9), resemble those documented in the case of atrioventricular valve dysplasia.

The fact that our postmortem examination revealed tricuspid valve dysplasia in all our animals that died with the symptoms of cardiorespiratory syndrome indicates the potential involvement of congenital heart defects in the etiology of this condition.

## References

1. Diman N. Y., Remacle S., Bertrand N., Picard J. J., Zaffran S., Rezsóhazy R.: A retinoic acid responsive Hoxa3 transgene expressed in embryonic pharyngeal endoderm, cardiac neural crest and a subdomain of the second heart field. *PLoS One* 2011, 6, e27624, doi: 10.1371/journal.pone.0027624.
2. Jaššo J.: Is the cardiopulmonary insufficiency syndrome of foxes a distemper virus infection? *Veterinářství* 1990, 40, 34-35.
3. Kopczeński A., Saba L., Bis-Wencel H., Sławoń J., Strzałkowski L., Ulewicz W.: Influence of taurine on the prevention and treatment of cardio-pulmonary syndrome in common foxes. *Med. Weter.* 1998, 54, 325-330.
4. Lisowska A., Sobkowicz B., Musiał W. J., Skibińska E.: Congenital tricuspid valve dysplasia in a patient with advanced heart failure. *Kardiol. Pol.* 2006, 63, 201-203.
5. Liu S. K., Tilley L. P.: Dysplasia of the tricuspid valve in the dog and cat. *J. Am. Vet. Med. Assoc.* 1976, 169, 623-630.
6. Martino P. E., Gimeno E. J., Parma A., Stanchi N. O., Bautista E., Petruccioli M. A.: Congestive cardiomyopathy in a fox colony. *Revue Med. Vet.* 2007, 158, 40-45.
7. Motz J., Rubaj B., Saba L., Sławoń J., Bis-Wencel H., Nozdryn-Plotnicki Z.: The anatomic and histopathological examination in the chronic cor pulmonale syndrome of foxes (*Vulpes vulpes*). *Med. Weter.* 1995, 51, 618-620.
8. Noszczyk-Nowak A., Piasecki T., Cepiel A., Nowak M., Janus I., Paślowska U.: Atrioventricular valvular anomalies and their role in etiopathogenesis of cardiorespiratory syndrome in farmed common foxes (*Vulpes vulpes*). *Vet. Quart.* 2016, 36, 16-21.
9. Onderka D. K.: Congestive heart failure in juvenile foxes, [in:] *Biology, pathology and genetics of fur bearing animals. Proceedings of the IV International Congress of Fur Animal Production.* (Murphy BD, Hunter DB, eds.) Aug 21-24 Rexdale (ON): Hudson's Bay Auctions House 1988.
10. Paślowska U., Noszczyk-Nowak A., Janiszewski A., Nicpoń J.: Tricuspid dysplasia in dogs. *Bull. Vet. Inst. Pulawy* 2013, 57, 123-126.
11. Saba L., Kopczeński A., Bis-Wencel H., Tymczyna L., Nowakowicz-Dębek B.: Indices of blood metabolic profile in foxes with lung-heart syndrome. *Scientific* 1998, 22, 55-58.
12. Saba L., Kopczeński A., Sławoń J., Bis-Wencel H., Tymczyna L.: Taurine in serum, bile and feed of foxes with lung-heart syndrome. *Scientific* 1998, 22, 59-61.
13. Snarr B. S., Kern C. B., Wessels A.: Origin and fate of cardiac mesenchyme. *Dev. Dyn.* 2008, 237, 2804-2819.
14. Wójcik J., Mizak B., Chrobocińska M., Kopczeński A., Saba L.: Attempts at evaluating the role of the viral agent in the etiology of cardiopulmonary syndrome in foxes. *Med. Weter.* 1996, 52, 647-648.
15. Wójcik J., Mizak B., Chrobocińska M., Saba L.: Virusological examination of foxes which died of a lung heart syndrome. *Anim. Prod. Rev.* 1996, 28, 177-178.

**Corresponding author: Prof. dr hab. Agnieszka Noszczyk-Nowak, Department of Internal and Diseases with Clinic for Horses, Dogs and Cats, Faculty of Veterinary Medicine, Wrocław University of Environmental and Life Sciences, Grunwaldzki Sq. 47, 50-366 Wrocław, Poland**