

# Diagnostic procedures and surgical treatment of craniodorsal coxofemoral luxation in a dwarf rabbit

© YAUHENI ZHALNIAROVICH<sup>1</sup>, © JOANNA BAJON<sup>1</sup>,  
© MAGDALENA MORAWSKA-KOZŁOWSKA<sup>1</sup>,  
© PAULINA PRZYBOROWSKA-ZHALNIAROVICH<sup>2</sup>, © KORINA MICHALSKA<sup>1</sup>

<sup>1</sup>Department of Surgery and Radiology with Clinic, <sup>2</sup>Department of Veterinary Public Health, Faculty of Veterinary Medicine, University of Warmia and Mazury in Olsztyn, Oczapowskiego 14, 10-718 Olsztyn, Poland

Received 14.11.2022

Accepted 30.12.2022

Zhalniarovich Y., Bajon J., Morawska-Kozłowska M., Przyborowska-Zhalniarovich P., Michalska K.

## Diagnostic procedures and surgical treatment of craniodorsal coxofemoral luxation in a dwarf rabbit

### Summary

To our knowledge, there are no sufficient reports on the full management of hip luxation in rabbits, including descriptions of the diagnostics procedure with the use of computed tomography, surgical procedure, and postoperative management with a measurable assessment of the results. The objective of this study was to report on a computed tomography examination of a coxofemoral joint in a rabbit, a surgical technique for the repair of craniodorsal coxofemoral dislocation, as well as short- and long-term postoperative outcomes. Craniodorsal coxofemoral luxation was diagnosed by physical examination and radiographic examination. A craniodorsal luxation of the femoral head and the presence of an intact femoral neck were confirmed by computed tomography. An ostectomy of the femoral head and neck was performed using a craniolateral open approach. The coxofemoral luxation was successfully reduced, and relaxation did not occur. At short- and long-term follow-ups, in parallel with clinical examination, an extensive pain assessment protocol was applied. CT proved to be a simple and effective technique and should be considered as an alternative to radiographic examination for diagnosis of coxofemoral luxation in rabbits. An immediate surgical intervention in hip dislocation in rabbits is necessary to alleviate pain associated with the movement of the injured joint and to avoid development of degenerative changes. In follow-up examinations after the procedure, a reliable assessment of postoperative pain and the effectiveness of perioperative analgesia should be made by introducing a postoperative pain assessment protocol. It could simplify an objective comparison between outcomes of different orthopaedic procedures in rabbits.

**Keywords:** hip luxation, computed tomography, surgical procedure, arthroplasty, pain assessment

Luxation of a coxofemoral joint is the most common joint luxation in companion animals (3, 20, 23). Although published data on the prevalence of coxofemoral luxation in rabbits are insufficient, several authors consider it as a common condition. The displacement of the femoral head from the acetabulum is associated mostly with a traumatic injury, but may also be due to congenital and iatrogenic factors (8, 12).

The diagnosis of coxofemoral luxation in rabbits has been limited to clinical and radiographic examinations (12). Although routinely used for evaluation of the coxofemoral joint in companion animal patients (13), computed tomography (CT) has not recently been reported as a method for examination of the rabbit's hip joint. The superiority of CT scans to conventional radiographs in detecting coxofemoral joint luxation in rabbits has not yet been assessed, and there are no

reports of direct comparison of radiographs and CT scans for the evaluation of hip luxation in rabbits.

In dogs and cats, the management of coxofemoral luxation is relatively standardized (3, 11, 15, 22, 24). The management of trauma cases in rabbits, compared to pet animals, is mostly empirical and requires a broader description.

A few articles have reported a successful treatment of traumatic coxofemoral luxation in rabbits by closed reduction, the iliofemoral suture technique, and the femoral head and neck ostectomy technique (FHNO) (1, 8, 12). However, this recommendation in rabbits must be viewed with caution, as comparisons between long-term functional outcomes of procedures in rabbits are insufficient. In addition, differences in the rate and severity of complications associated with each procedure have not been widely investigated.

It is important to evaluate changes in objective measurements, as well as the quality of life after the procedure on the basis of the owner's daily observations (12, 19, 21).

Since there are no reports describing a complete surgical treatment protocol for coxofemoral luxation in rabbits, the aim of our study was to report and briefly describe (i) the use of computed tomography for the diagnosis of hip luxation in rabbits, (ii) the osteotomy of the femoral head and neck along with postoperative care, and (iii) the long-term outcome of the procedure.

### Case presentation

An eight-month-old male dwarf rabbit weighing 0.8 kg with coxofemoral luxation was admitted to the clinic of the Department of Surgery and Radiology for evaluation and treatment.

**Clinical findings.** The rabbit was able to rise unassisted. After a general clinical examination, the pelvic region and the hip joints were examined clinically with the rabbit standing, walking, and in lateral recumbency. An X-ray image was taken in the ventral-dorsal plane in recumbency (Fig. 1). A dislocation of the right coxofemoral joint was suspected from the results of a full orthopedic examination. For further diagnosis, a CT was recommended. With the use of computed tomography, the surgeon was able to accurately plan the procedure on the basis of the spatial imaging of the injury. Currently, this technique is used for orthopedic imaging in small animals. It makes it possible to create models with a 3D printer and to improve treatment planning (2).

**Preoperative computed tomography.** The patient was premedicated with a mixture of dexmedetomidine (Dexdomitor, Orion Pharma, 0.5 mg/ml), ketamine (Bioketan, Vetoquinol, 100 mg/ml), and buprenorphine (Bupaq, Orion Pharma, 0.3 mg/ml). Enrofloxacin was also administered (Enrobioflox, Vetoquinol, 5%). After sedation, anesthesia was induced with 3-5% isoflurane solution (Iso-Vet 250 ml, Piramal Critical Care B.V., 100%) in a stream of oxygen. Then CT examination was performed with a Siemens Healthcare Somatom Duo Emotion CT machine at 130 kV, 90 mA, and a slice thickness of 1 mm. The animal was placed in recumbency with hind limbs adducted caudally. The CT results were analyzed on the "bone window", and a three-dimensional (3D) model was generated to plan the therapeutic procedure. The craniodorsally luxated femoral head was visible on CT scans (Fig. 1, Fig. 2); no fractures were identified. Based on the diagnostic features, FHNO was recommended for treatment.

**Surgical technique.** The rabbit was anesthetized with 3-5% isoflurane solution (Iso-Vet 250 ml, Piramal Critical Care B.V., 100%) in a stream of oxygen and positioned in lateral recumbency with the affected limb uppermost. The hip joint was exposed through a cranio-lateral approach. A 5 cm skin incision was made, beginning 1 cm from the dorsal edge of the joint and along the cranial edge of the femur. Subcutaneous tissues were separated from the underlying fascia, and the abductor muscle of the thigh was retracted in the caudal direction. The aponeurosis between the caudal part of the tensor fasciae latae muscle and the cranial part of the head of the biceps femoris muscle was incised (Fig. 3A).

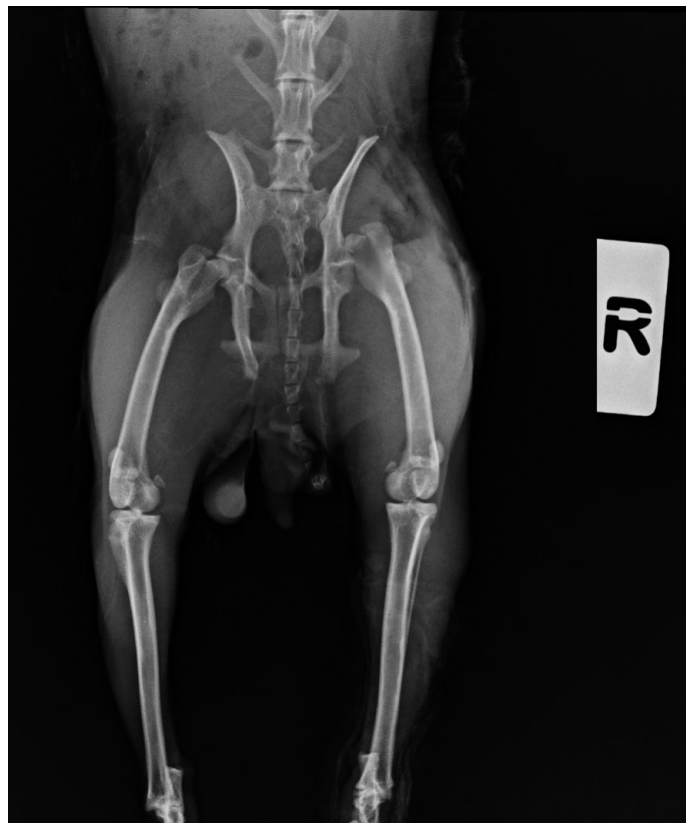

Fig. 1. An X-ray image showing a craniodorsal coxofemoral luxation of the right hip joint

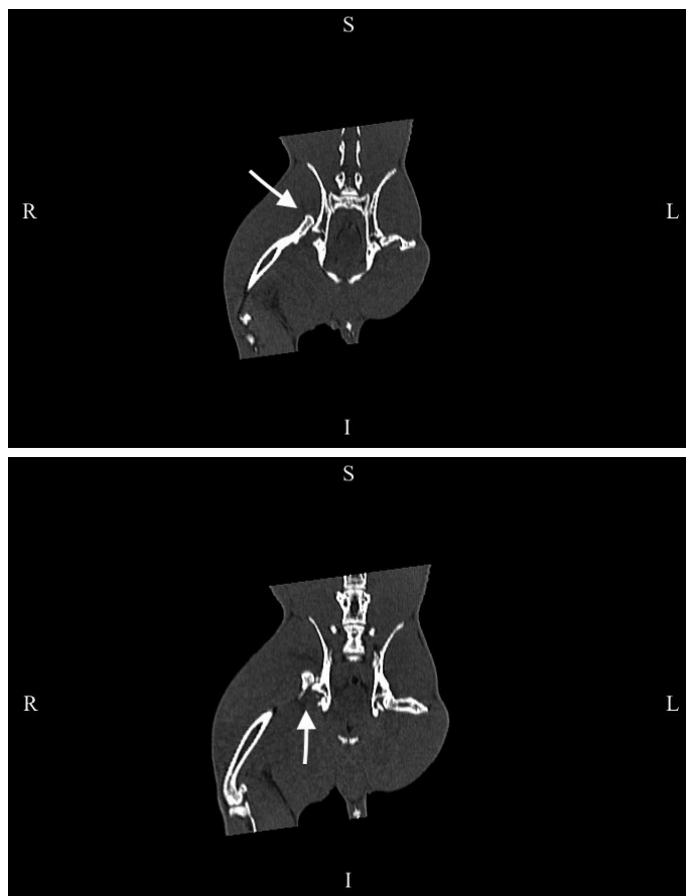


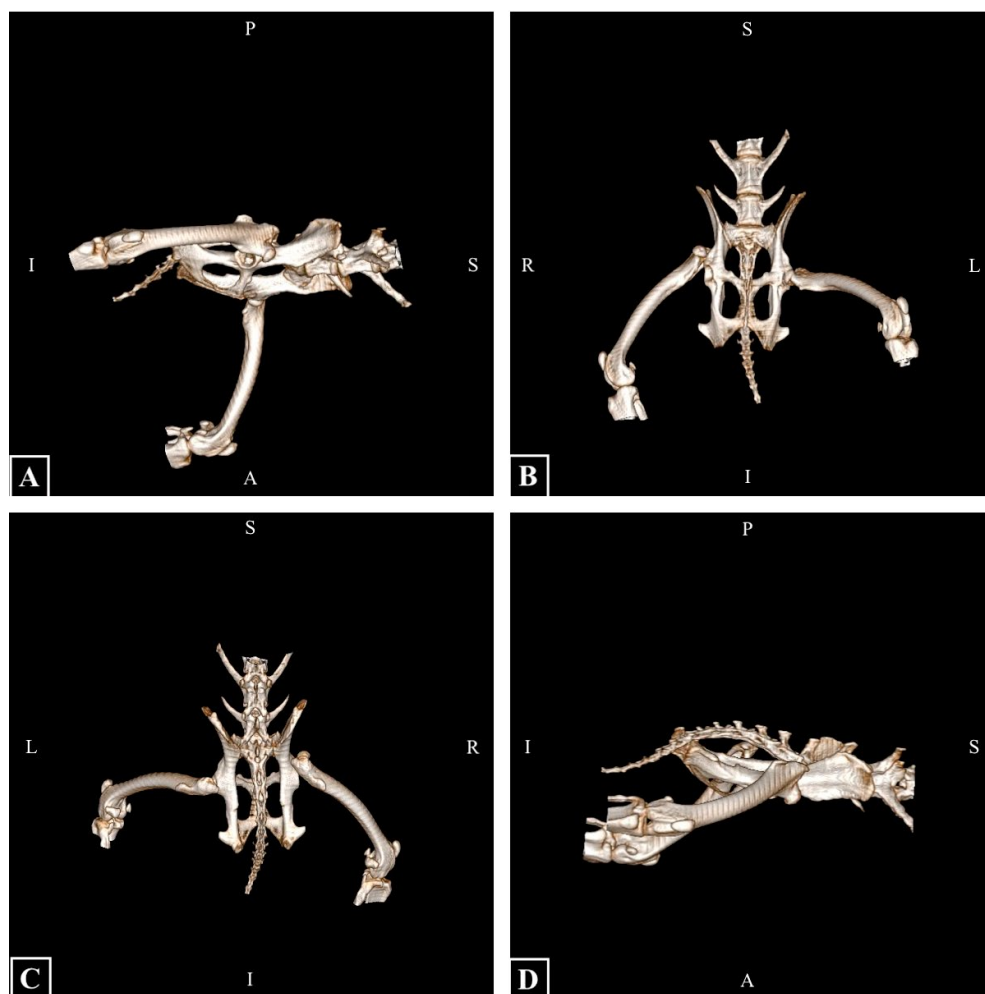
Fig. 2. CT of the rabbit's coxofemoral joints in a dorsal position on the "bone window". A displacement of the femoral head beyond the acetabulum of the hip joint on the right side is visible (arrow)

As the next step, the gluteus superficialis was separated from the deep structures of the tensor fasciae latae by incision. The gluteus medius was separated by blunt dissection and retracted in the caudal direction to expose the right coxofemoral joint. The joint capsule was damaged, and the affected leg was externally rotated to better visualize the joint. Damaged fragments of the ligament of the femoral head were removed. The vastus medialis was lifted from the short femoral neck. The limb was maintained in external rotation, and the knee was pushed towards the surgical table. The femoral head was stabilized with the use of Hohmann retractors (Fig. 3B).

The incision line was marked on the femur with the sharp edge of the osteotome. The osteotomy was performed with an oscillating saw positioned perpendicular to the surgical table, with routine saline irrigation (Fig. 3C). The smoothness of the osteotomy margin and the integrity of the lesser trochanter were checked. Rough edges were smoothed with a small rasp (Fig. 3D). The osteotomy site of the femur was lavaged with isotonic saline (0.9% NaCl).

The articular capsule was closed with two interrupted sutures using absorbable material. Muscles and fascia were stabilized with two layers of mattress sutures. Subcutaneous tissues were closed with intradermal sutures, and superficial skin layers were closed with surgical staples. Postoperative radiograms confirmed that the surgical procedure was performed correctly and hip dislocation was reduced (Fig. 4).

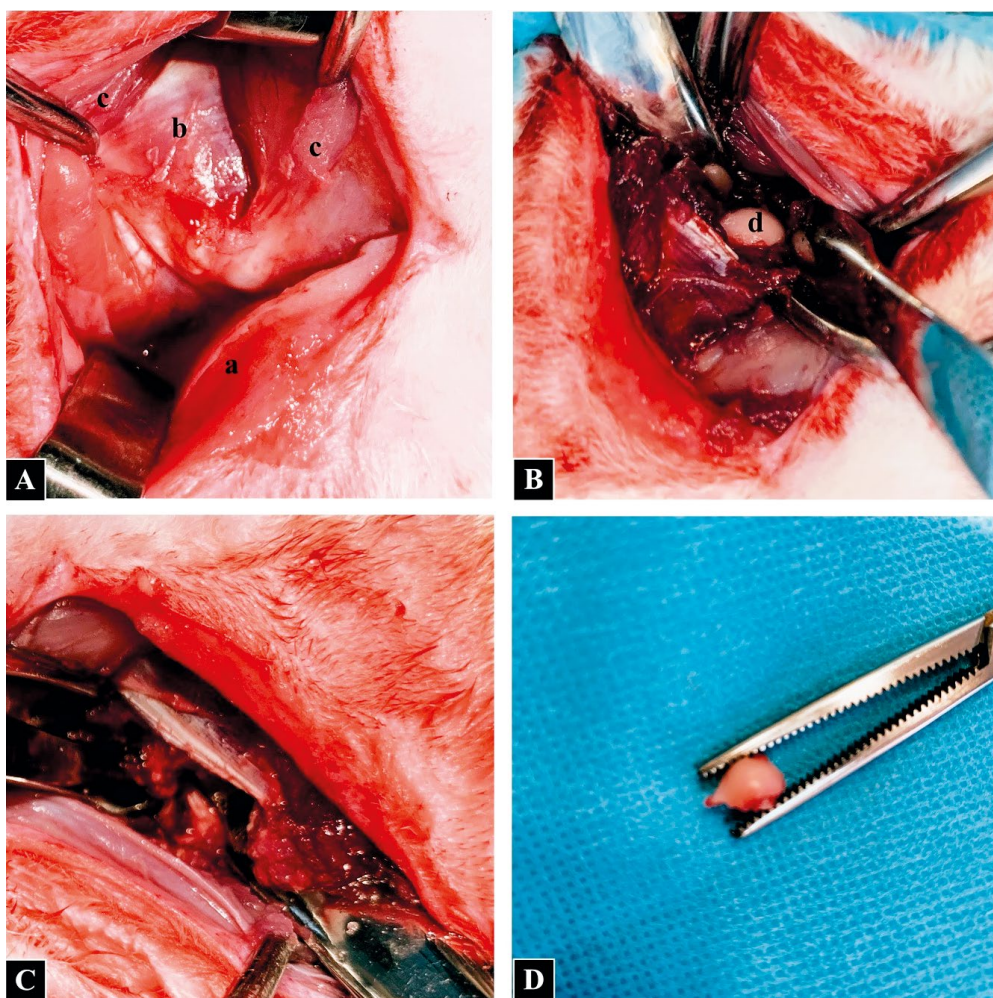
**Postoperative care.** For the first 3 days after surgery, the hind limbs were hobbled so that the rabbit could rise and stand with assistance. The clinical assessment of postoperative pain was conducted on the basis of The Rabbit Grimace Scale (RbtGS) (16), a composite pain scale for assessing and quantifying pain in rabbits (CANCRS) (4), and behavioral changes (21) for 3 days after surgery by the veterinarian in charge. After discharge, the assessment of postoperative pain was continued by the owner on the basis of The Rabbit Grimace Scale (RbtGS) (16) and behavioral changes (21). Skin sutures were removed 14 days after surgery. Enrofloxacin (10 mg/kg twice daily, subcutaneously) was administered preoperatively and continued for 7 days at the same dose p.o. This antibiotic was preferred over penicillins due to its lower toxicity and lower risk of enterocolitis in rabbits (18). The rabbit was administered a multimodal analgesia regimen for 3 days after surgery, a combination of buprenorphine (100 µg/kg once daily i.m.) and meloxicam (0.6 mg/kg once daily s.c.). After discharge, the owner



**Fig. 3.** A 3D reconstruction of the rabbit's coxofemoral joints in sagittal (A, D), ventral (B), and dorsal (C) positions. Confirmation of cranio-dorsal hip luxation on the right side based on CT scans

was instructed to limit the rabbit's movement by placing it in a small enclosure on flat, non-slippery ground for at least 6 weeks after surgery. A meloxicam was prescribed at discharge at a dose of 0.6 mg/kg once a day given orally for 7 days. The owner was instructed and asked to continue pain assessment after discharge for 2 weeks after surgery.

**Postoperative development.** During the initial days after the surgery, the rabbit put limited weight on the operated limb. The general condition of the rabbit improved significantly 5 days after surgery. Table 1 and Table 2 present clinical pain assessment involving the RbtGS scale, the CANCRES scale, and behavior (16, 21). A clinical examination two weeks after the treatment revealed a good surgical outcome; the limb attitude and the position of the greater trochanter were normal, but there was still slight lameness. The surgical site healed without complication. Two months after the surgery, the range of motion of the affected limb was fully restored without any symptoms of pain, and the patient's condition was described as excellent. With this technique, the femoral head and acetabulum's bony contact was minimized to make space for the development of an artificial joint (pseudoarthrosis) composed of dense fibrous tissue (15). The osteotomy site was completely healed eight months after the procedure, and a clinical examination confirmed that normal hip biomechanics were restored. Complications or side effects were not observed.



**Fig. 4.** The successive steps of the surgical procedure. (A) Abductor muscle of the thigh retracted in the caudal direction (a); biceps femoris muscle (b); tensor fasciae latae muscle separated from the remaining muscles by an incision in the aponeurosis (c). (B) Hohmann retractors placed on the cranial and caudal aspects of the femoral head. The limb was maintained in external rotation to expose the femoral head (d). (C) Surgical site after resection. (D) Head and neck of the femur after resection

**Tab. 1.** Pattern and scoring of CANCRS (4) during the first 3 days after surgery

Parameters			Day of treatment			
			0*	1	2	3
CANCRS	RbtGS	Orbital tightening [0-2]	2	2	1	1
		Cheek flattening [0-2]	2	1	1	0
		Nostril shape [0-2]	2	1	1	1
		Whisker position [0-2]	2	1	1	1
		Ear position [0-2]	2	2	2	1
	CPS	Pupilla dilation [0-1]	1	1	1	1
		Heart rate percentage increase – based on 250 beats/min [0-2]	2	2	1	1
		Respiratory rate – based on 60 breaths/min [0-3]	2	2	1	1
		Respiratory pattern [0-1]	1	1	1	0
		Palpation of the painful area [0-2]	2	2	2	1
		Mental status [0-2]	2	2	1	1
		Vocalization [0-3]	0	0	0	0
<b>Score</b>		<b>20</b>	<b>17</b>	<b>13</b>	<b>9</b>	

Explanations: the scores were divided into four classes: no pain (NP), discomfort (D), moderate pain (MP), severe pain (SP); ranges of the scores for each class of pain in CANCRS: NP 0-5, D 6-11, MP 12-17, SP 18-24; \* day of surgery

## Discussion and conclusions

Compared to plain radiographs, CT scans have been shown to provide a better view of the traumatic coxofemoral luxation, position of the luxated fragments, and osteochondral fractures or marginal fracture lines. CT makes it possible to obtain 3D images and recognize pathologic changes that cannot be detected by conventional radiographs. Moreover, CT scans are less influenced than conventional radiographs by patient positioning, body habitus, and technical factors. As a result, CT scans have been increasingly used in the decision-making process regarding the treatment of coxofemoral joint disabilities in companion animals (6, 13, 20).

To the best of the authors' knowledge, CT scans of coxofemoral luxation in rabbits have not been presented in the literature before. 3D imaging methods, such as CT or magnetic resonance imaging (MRI), are not only the modality of choice in evaluating animals' models of selected human diseases, but they are also very popular in veterinary clinical practice. Pet owners prefer CT over MRI due to lower cost and greater availability (14). In the case described here, CT scans revealed that there was no acetabular trauma or fracture of others bone structures of the pelvis and femur. Moreover, the 3D reconstruction obtained was used to plan the surgical procedure.

Various treatment options are available for managing hip luxation in rabbits. Closed reduction with the application of the Ehmer sling and cage confinement is a popular method. In 2018, Gallego described four cases in which the closed reduction technique was used to treat coxofemoral

Tab. 2. Pattern and scoring of RbtGS (16) and behavioral changes (20) during the first 14 days after surgery

Parameters	Day of treatment														
	0*	1	2	3	4	5	6	7	8	9	10	11	12	13	14
RbtGS score**	10	7	6	4	2	1	0	0	0	0	0	0	0	0	0
Decreased food intake	+	+	+	+	+	+	-	-	-	-	-	-	-	-	-
Drinking more	+	+	+	+	-	-	-	-	-	-	-	-	-	-	-
Decreased faecal output	+	+	+	+	+	+	+	+	+	-	-	-	-	-	-
Abnormal posturing	+	+	+	+	+	+	+	+	-	-	-	-	-	-	-
Hunched back	+	+	+	+	+	-	-	-	-	-	-	-	-	-	-
Putting weight on and raising the affected limb	+	+	+	+	+	+	+	+	-	-	-	-	-	-	-
Reluctance to move	+	+	+	+	+	+	-	-	-	-	-	-	-	-	-
Suspended limb	+	+	+	+	-	-	-	-	-	-	-	-	-	-	-
Licking affected area	not noticed														
Grinding teeth	not noticed														
Increased respiratory rate	+	+	+	-	-	-	-	-	-	-	-	-	-	-	-
Loss of bodyweight	not noticed														
Hiding behavior	+	+	+	+	-	-	-	-	-	-	-	-	-	-	-
Aggression towards handlers	+	+	+	+	-	-	-	-	-	-	-	-	-	-	-
Thumping the hind feet	not noticed														
Running away when approached	+	+	+	+	-	-	-	-	-	-	-	-	-	-	-

Explanations: \* day of surgery; \*\* ranges of the scores for each class of pain in RbtGS: no pain 0-1, discomfort 2-4, moderate pain 5-7, severe pain 8-10; changes in behavior: + present, - absent

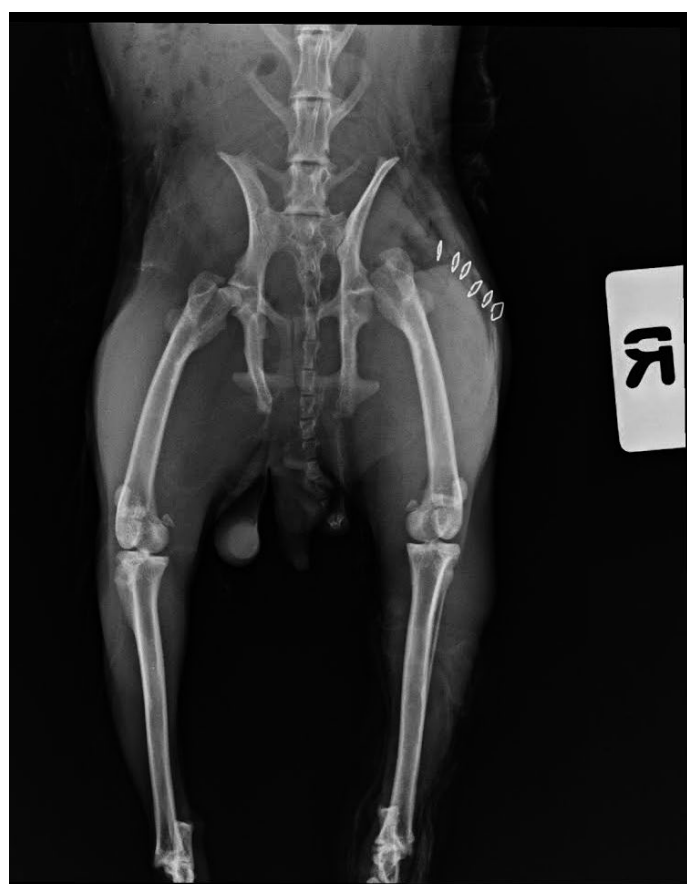

Fig. 5. A ventrodorsal postoperative radiograph of the pelvis and hind limbs of the rabbit. The resected femoral head and neck on the right side

luxation in rabbits, but a satisfactory outcome was noted in only 50% of the cases. In 50% of the patients, relaxation occurred within 24 hours of the surgical procedure (12). The treatment of the other patients lasted five months. Treatment is relatively short, but the long-term outcomes of closed reduction are questionable. Therefore, this method should be regarded as relatively ineffective in the treatment of hip dislocation in rabbits.

Open surgery is required when closed reduction is ineffective or when the femoral head is completely displaced

from the acetabulum (8, 11, 15). In rabbits, coxofemoral luxation can be managed by two open reduction methods: extracapsular stabilization with iliofemoral nylon sutures combined with capsular reconstruction and resection arthroplasty of the femoral head. Clinical cases in which hip dislocation was managed by extracapsular stabilization have been described. Lameness in the affected limb was completely eliminated, and the patient's quality of life visibly improved. However, this technique involves a long convalescence period. In the study by Gallego, full recovery was achieved after 12 months in 50% of the patients, and after 18 months in the remaining patients. In the most successful case, lameness was eliminated after two months (12).

FHNO is a salvage procedure intended to alleviate pain associated with the movement of a diseased or injured coxofemoral joint in companion animals, which allows the affected leg to return to function without the use of prosthetic implants (3, 8, 11, 12, 15, 23, 24). Rabbits are ideal candidates for resection arthroplasty because of their anatomy of the musculoskeletal system in the pelvic limbs (8, 19). Rabbits have well-developed pelvic limb muscles. Two anatomical structures that play an important role in hip biomechanics in rabbits are the lesser trochanter, which maintains the functional connection of the iliopsoas muscle, and the femoral neck, which is shorter than in dogs and cats. These anatomical adaptations can theoretically make postoperative recovery in rabbits faster than in other companion animals because the hip joint is stabilized by

well-developed muscle groups rather than osseous structures (7). In the study by Gallego, satisfactory outcomes were reported in 100% of rabbits treated by osteotomy of the femoral neck and head. Lameness was eliminated after 15 days, and full recovery was achieved after seven months (12). Femoral head osteotomy is a better solution than extracapsular stabilization because it speeds up recovery, improves the quality of the patient's life, and, consequently, increases the owner's satisfaction. In the case described here, resection arthroplasty of the femoral head also produced highly satisfactory results and effectively eliminated lameness. Due to faster recovery and a more satisfactory clinical outcome, FHNO can be regarded as a standard for managing coxofemoral luxation in rabbits.

Analgesia in companion animals has improved over recent years. However, pain assessment is still limited in rabbits. The lack of multimodal composite pain scales specific for rabbits makes evaluation very challenging (5). Thus, the most applicable methods for real-time clinical pain measurement are based on the evaluation of behavioral changes and facial expressions (RbtGS) and a scale including clinical parameters (CANCRS) (4, 16, 21). Orthopedic pain is expected to be intense and associated with specific behaviors (e.g. lameness) and other behavioral changes (4, 5, 9, 10, 16, 17, 21). To our knowledge, no publication on the surgical management of coxofemoral luxation has discussed postoperative pain management or postoperative care in rabbits undergoing orthopedic surgery.

The present article gives a detailed summary of the procedure in the case of suspected coxofemoral luxation in the rabbit, including imaging diagnostics with the use of CT, surgery, and postoperative management with the evaluation of the results of postoperative analgesia and long-term outcomes.

In the management of coxofemoral luxation in rabbits, computed tomography should be considered as a complementary imaging modality to radiography. Currently, there is no gold standard for pain assessment in rabbits undergoing orthopedic surgery, so a comprehensive assessment could be useful in clinical practice to improve pain management after orthopedic procedures. Due to faster recovery and a more satisfactory clinical outcome, osteotomy of the femoral head and neck can be regarded as a standard for managing coxofemoral luxation in rabbits.

### List of abbreviations

CT – computed tomography  
 FHNO – femoral head and neck osteotomy  
 3D – three dimensional  
 RbtGS – The Rabbit Grimace Scale  
 CANCRS – composite pain scale for assessing and quantifying pain in rabbits  
 MRI – magnetic resonance imaging  
 i.m. – intramuscular  
 s.c. – subcutaneous

### References

1. *Abedi G. H., Asghari A., Alizadeh R.*: Histopathological and radiological evaluation of a modified arthroplasty hip joint in rabbit. *J. Comp. Pathobiol.* 2013, 1, 39, 803-809.
2. *Alemayehu D. G., Zhang Z., Tahir E., Gateau D., Zhang D.-F., Ma X.*: Preoperative planning using 3D printing technology in orthopedic surgery. *Biomed Res. Int.* 2021, 12, 2021, 7940242.
3. *Ash K., Rosselli D., Danielski A., Farrell M., Hamilton M., Fitzpatrick N.*: Correction of craniodorsal coxofemoral luxation in cats and small breed dogs using a modified Knowles technique with the braided polyblend TightRope™ systems. *Vet. Comp. Orthop. Traumatol.* 2012, 25 (01), 54-60.
4. *Banchi P., Quaranta G., Ricci A., Mauthe von Degerfeld M.*: Reliability and construct validity of a composite pain scale for rabbit (CANCRS) in a clinical environment. *Clegg S. R. (ed.) PLOS ONE* 2020, 30, 15 (4), e0221377.
5. *Benato L., Murrell J. C., Blackwell E. J., Saunders R., Rooney N.*: Analgesia in pet rabbits: a survey study on how pain is assessed and ameliorated by veterinary surgeons. *Vet. Rec.* 2020, 186 (18), 603-603.
6. *Brooks R., Ribbans W. O. B.*: Diagnosis and imaging studies of traumatic hip dislocations in the adult. *Clin. Orthop.* 2000, 1, 377, 15-23.
7. *Channon S., Payne R., Wilson A.*: Functional specialisation of the pelvic limb of the hare (*Lepus europeus*). *J. Anat.* 2007, 1, 210, 472-490.
8. *Coleman K. A., Palmer R. H., Johnston M. S.*: Femoral head and neck osteotomy for surgical treatment of acute craniodorsal coxofemoral luxation in rabbits. *J. Exot. Pet. Med.* 2015, 24 (2), 178-182.
9. *Coulter C. A., Flecknell P. A., Leach M. C., Richardson C. A.*: Reported analgesic administration to rabbits undergoing experimental surgical procedures. *BMC Vet. Res.* 2011, 7 (1), 12.
10. *DiVincenti L., Meirelles L. A. D., Westcott R. A.*: Safety and clinical effectiveness of a compounded sustained-release formulation of buprenorphine for postoperative analgesia in New Zealand White rabbits. *J. Am. Vet. Med. Assoc.* 2016, 248 (7), 795-801.
11. *Fitzpatrick N., Pratola L., Yeadon R., Nikolaou C., Hamilton M., Farrell M.*: Total hip replacement after failed femoral head and neck excision in two dogs and two cats: Conversion THR after FHNE. *Vet. Surg.* 2012, 41 (1), 136-142.
12. *Gallego M., Villaluenga J. E.*: Coxofemoral luxation in pet rabbits: nine cases. *J. Small Anim. Pract.* 2019, 60 (10), 631-635.
13. *Ginja M. M. D., Ferreira A. J., Jesus S. S., Melo-Pinto P., Bulas-Cruz J., Orden M. A.*: Comparison of clinical, radiographic, computed tomographic, and magnetic resonance imaging methods for early prediction of canine hip laxity and dysplasia. *Vet. Radiol. Ultrasound.* 2009, 50 (2), 135-143.
14. *Glodek J., Adamiak Z., Przeworski A.*: Magnetic resonance imaging of reptiles, rodents, and lagomorphs for clinical diagnosis and animal research. *Comp. Med.* 2016, 1, 66, 1-4.
15. *Harper T. A. M.*: Femoral head and neck excision. *Vet. Clin. North Am. Small Anim. Pract.* 2017, 47 (4), 885-897.
16. *Keating S. C. J., Thomas A. A., Flecknell P. A., Leach M. C.*: Evaluation of EMLA cream for preventing pain during tattooing of rabbits: changes in physiological, behavioural and facial expression responses. *Chapouthier G. (ed.) PLoS ONE* 2012, 7, 7 (9), e44437.
17. *Leach M. C., Allweiler S., Richardson C., Roughan J. V., Narbe R., Flecknell P. A.*: Behavioural effects of ovariohysterectomy and oral administration of meloxicam in laboratory housed rabbits. *Res. Vet. Sci.* 2009, 2, 336-347.
18. *Morris T. H.*: Antibiotic therapeutics in laboratory animals. *Lab. Anim.* 1995, 29, 16-36.
19. *Owiny J., Vandewoude S., Painter J., Norrdin R., Veeramachaneni D.*: Hip dysplasia in rabbits: Association with nest box flooring. *Comp. Med.* 2001, 1, 51, 85-88.
20. *Perry K.*: Feline hip dysplasia: A challenge to recognise and treat. *J. Feline Med. Surg.* 2016, 18 (3), 203-218.
21. *Pinho R. H., Leach M. C., Minto B. W., Rocha F. D. L., Luna S. P. L.*: Postoperative pain behaviours in rabbits following orthopaedic surgery and effect of observer presence. *Staffieri F. (ed.) PLOS ONE* 2020, 22, 15 (10), e0240605.
22. *Pinna S., Lanzi F., Tassani C., Mian G.*: Intra-articular replacement of a ruptured cranial cruciate ligament using the Mini-TightRope in the dog: a preliminary study. *J. Vet. Sci.* 2020, 21 (5), e53.
23. *Trostel C. T., Fox D. B.*: Coxofemoral joint luxation in dogs treated with toggle rod stabilization: a multi-institutional retrospective review with client survey. *J. Am. Anim. Hosp. Assoc.* 2020, 1, 56 (2), 83-91.
24. *Yap F. W., Dunn A. L., Garcia-Fernandez P. M., Brown G., Allan R. M., Calvo I.*: Femoral head and neck excision in cats: medium- to long-term functional outcome in 18 cats. *J. Feline Med. Surg.* 2015, 17 (8), 704-710.

**Corresponding author: Magdalena Morawska-Kozłowska, DVM, Oczapowskiego 14, 10-718 Olsztyn, Poland; e-mail: magdalena.m.morawska@gmail.com**