

# The effect of the high-intensity laser therapy on dorsal metacarpal disease in 2-year-old Thoroughbreds

© KAROLINA ŚNIEGUCA<sup>1</sup>, © MARIA SOROKO-DUBROVINA<sup>1</sup>,  
© PAULINA ZIELIŃSKA<sup>2</sup>, © KRZYSZTOF D. DUDEK<sup>3</sup>

<sup>1</sup>Institute of Animal Breeding, Wrocław University of Environmental and Life Sciences, Chelmońskiego 38C, 51-160 Wrocław, Poland

<sup>2</sup>Department of Surgery, Wrocław University of Environmental and Life Sciences, pl. Grunwaldzki 51, 50-366 Wrocław, Poland

<sup>3</sup>Regional Center for Digital Medicine, 4<sup>th</sup> Military Clinical Hospital, Rudolfa Weigla 5, 50-981 Wrocław, Poland

Received 25.01.2026

Accepted 26.03.2026

Śnieguca K., Soroko-Dubrovina M., Zielińska P., Dudek K. D.

## The effect of the high-intensity laser therapy on dorsal metacarpal disease in 2-year-old Thoroughbreds

### Summary

Dorsal metacarpal disease (DMD) is one of the most prevalent musculoskeletal injuries in young Thoroughbreds. The study tested the hypothesis that high-intensity laser therapy (HILT), used as the sole therapeutic intervention in horses with DMD, reduces the severity of clinical signs such as pain and lameness compared with horses withdrawn from training but not receiving treatment. During the 2023 and 2024 racing seasons, thermographic examinations were conducted to monitor changes in body surface temperature, alongside orthopedic examination and radiographic examination of the third metacarpal bones. 16 horses were diagnosed with DMD. 11 horses from this group underwent a series of laser treatments (HILT-treated group), while 5 horses were included in the control group, which did not receive laser therapy. The treatment protocol consisted of five HILT sessions administered daily, followed by an additional five sessions administered every other day. To assess the effects of HILT, thermographic and orthopedic examinations of both metacarpal bones were conducted before and after each laser therapy session. Furthermore, radiographic examination and blood sample analyses were performed before and after the completion of the treatment sessions. Additionally, the same procedures were carried out in the control group. The results demonstrated a reduction in pain and lameness in horses treated with HILT. These findings suggest that HILT may alleviate clinical signs associated with DMD, although further studies are required to determine its effect on the healing process and treatment duration.

**Keywords:** Dorsal Metacarpal Disease, HILT, Thoroughbreds

In recent years, high-intensity laser therapy (HILT) has gained recognition as a therapeutic modality in equine veterinary medicine and physiotherapy (16, 20, 22, 40). The properties of HILT facilitate therapeutic support for various orthopedic and muscular disorders in sport horses (12, 38, 58, 60). HILT is a non-invasive and painless technique (6) that operates at a high peak power (1-3 kW) and a wavelength of 1064 nm, combined with a low frequency (30 Hz) and an average power of 6 W (1), allowing deep soft tissue irradiation. The laser light penetrates deeply, delivering substantial multidirectional energy to tissues and promoting regenerative processes (8, 46). Studies in humans have reported multiple positive effects of HILT, including analgesia and modulation of inflammatory responses

(14, 28, 31, 35, 42, 45, 54). Santamato et al. (42) observed significant reductions in pain, accompanied by improvements in muscle strength and functional outcomes. HILT has also been shown to reduce edema, likely through enhanced microvascularization and tissue perfusion (1, 21, 24). These properties provide a rationale for tissue repair and regeneration. Despite the documented benefits in humans and other species, the effects of HILT on bone injuries in horses, including distal metacarpal disease (DMD), remain largely unexplored (7, 46, 55, 57). This gap underscores the need to investigate its potential therapeutic role in equine orthopedic injuries, focusing on acceleration of bone healing and reduction of clinical recovery time.

Research on human subjects further indicates that HILT facilitates biological processes such as collagen synthesis, fibroblast ontogenesis (18), and increased tendon tensile strength (27).

An increasing number of equine orthopedic cases successfully treated with HILT have been reported in the literature (41). A study on equine bone marrow-derived mesenchymal stem cells demonstrated that laser light exerts an anti-inflammatory effect by inhibiting the synthesis of pro-inflammatory cytokines at the transcriptional level (37). Additionally, a randomized study involving 12 warmblood horses with injuries to the lateral suspensory branches showed significantly improved ligament lesion healing after four weeks of HILT treatment. Another study, which randomly assigned 26 horses with tendinopathies to HILT treatment, reported significant reductions in pain, swelling, and lameness after a series of 15 treatment sessions (58). However, in equine medicine, the application of HILT for bone injuries has not yet been scientifically documented. In contrast, studies conducted on human subjects have demonstrated the effectiveness of HILT in the treatment of degenerative diseases (31, 43, 53). In our previous study on horses diagnosed with bone spavin, we observed a reduction in tarsal joint pain, leading to a visible improvement in lameness following ten sessions of HILT (60). Since there are positive results for tarsal joint pain, it would be worthwhile to explore other skeletal disorders as well.

Dorsal metacarpal disease (DMD), represents one of the most prevalent musculoskeletal injuries in young Thoroughbreds (9, 15, 32, 33). This condition results from the accumulation of repetitive stress injuries, wherein cumulative mechanical loading leads to tissue failure (29, 36). Additionally, repetitive biomechanical imbalances contribute to tissue damage (30). Clinical signs of DMD include lameness, localized heat, swelling, and pain in palpation examination (32, 34). The observed features correspond to overload-related periostitis of the third metacarpal bone, characterized by a mechanically induced inflammatory reaction of the periosteum that drives accelerated bone turnover and predisposes to the development of periosteal microdamage (9, 32). As inflammation progresses, increased levels of inflammatory markers, including white blood cells, serum amyloid A, and fibrinogen, may be detected in the bloodstream (11, 52). However, few studies have examined these parameters in the context of monitoring inflammatory processes in horses undergoing regular training (3, 4), and no research to date has specifically investigated their levels during the onset of DMD.

The tissue damage is typically diagnosed on the dorsal aspect of the third metacarpal bone within the first six months of race training (33, 44). Standard treatment for affected horses includes administering phenylbutazone, applying ice water therapy, and hand-walking until soreness subsides. Horses then return to

a modified training regimen (33). Based on evidence from human studies demonstrating the effectiveness of HILT in promoting bone tissue repair (43, 53), this study aimed to evaluate the effect of HILT on the treatment of DMD in two-year-old Thoroughbred racehorses. We hypothesized that HILT, used as the sole therapeutic intervention in horses with DMD, reduces the severity of clinical signs such as pain and lameness compared to horses withdrawn from training but not receiving treatment.

## Material and methods

The research project protocol was approved by the Local Ethics Committee for Animal Experiments in Wrocław, Poland (No. 043/2023).

**Animals and data collection.** This study was conducted on 16 two-year-old Thoroughbreds with DMD during the 2023 and 2024 season at the Partynice Racecourse in Wrocław, Poland. Each season, the studies were performed from April through September. All horses had a comparable level of fitness and followed a standardized daily training regimen, which consisted of trotting for a distance of 1,000 meters, followed by speed training ranging from 200 to 500 meters. Prior to participation, all horses underwent comprehensive clinical and orthopedic examinations, conducted in accordance with the guidelines outlined by Stashak (15), to confirm their soundness. These examinations were performed by a single veterinarian, and soundness was determined using an objective assessment method.

Once the horses had been deemed clinically sound, a standardized monitoring protocol was initiated to track potential physiological responses over time. This included weekly thermographic assessments of the distal forelimbs, performed from a dorsal aspect, to detect changes in the body surface temperature of the third metacarpal bones. Radiographic projections of both forelimbs were obtained for each horse on the day of study commencement. Additionally, palpation of the distal forelimbs was performed to detect swelling, pain, or increased heat on the dorsal surface of the third metacarpal bones. Each examination was performed by a veterinarian (K.Ś.) with three years of experience in equine orthopedics. Across both racing seasons, sixteen horses diagnosed with DMD showed clinical manifestations such as an increased body surface temperature and pain. According to previous studies, a temperature difference of  $\geq 1.25^{\circ}\text{C}$  on the dorsal aspect of the metacarpal bone is indicative of a pathological condition (44). On the day the changes were detected on the third metacarpal bone, the horses did not show any pathological skin changes. The skin over the metacarpal bone was intact and had no breaks in continuity. Additionally, pressing on the dorsal surface of the third metacarpal bone caused discomfort and pain. Out of 16 horses with DMD, 11 horses were assigned randomly to the treatment group with HILT (HILT-treated group), while 5 horses with DMD were assigned to the control group without HILT. All horses enrolled in the study were excluded from training activities throughout the study period.

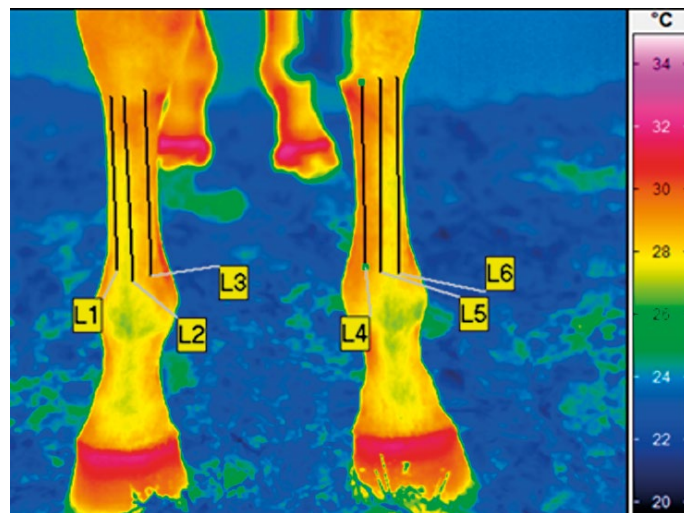
Sixteen horses diagnosed with unilateral DMD were enrolled in the study. Among these cases, six horses exhibited DMD in the left forelimb and ten in the right forelimb.

Ultimately, 16 forelimbs were affected by the disease process, and 16 forelimbs were healthy. No additional treatments were administered to the horses during the study period.

The HILT protocol consisted of ten sessions (S1-S10), with five consecutive daily sessions followed by five sessions administered every other day, performed while the horses were at rest. To evaluate the effects of HILT, thermographic and orthopedic examinations of both metacarpal bones were conducted before and immediately after each laser treatment session. Furthermore, radiographic imaging and blood sample analyses (including leukocyte count, serum amyloid A, and fibrinogen levels) were performed before and after the completion of all ten treatment sessions. The control group did not undergo the HILT procedure; however, thermographic and radiological examinations, as well as blood sampling, were performed concurrently with the HILT-treated group. The veterinarian was blinded with regard to the horses being examined.

**Thermographic examination.** Thermographic examinations were conducted using a calibrated VarioCam HR infrared camera (uncooled microbolometer focal plane array, sensor resolution of  $640 \times 480$ , spectral range of  $7.5\text{-}14 \mu\text{m}$ , noise equivalent temperature difference  $< 20 \text{ mK}$  at  $30^\circ\text{C}$ , normal lens with an instantaneous field of view (IFOV) of  $0.57 \text{ mrad}$ , and a measurement uncertainty of  $\pm 1\%$  across the overall temperature range; InfraTec, Dresden, Germany). The examinations followed a standardized thermographic protocol based on previous studies (17, 44, 59). Thermographic imaging was performed in a brick racing stable characterized by high thermal inertia, which ensured relatively stable indoor microclimatic conditions throughout the study period. The ambient temperature in the examination area was monitored immediately before and during each measurement and was maintained within the range of  $17\text{-}20^\circ\text{C}$ , irrespective of external environmental conditions. At each session, the ambient temperature and humidity in the stable was measured by a TES 1314 thermometer (TES, Taipei, Taiwan). Prior to imaging, each horse underwent a 20-minute acclimatization period outside its stall (47). To minimize environmental influences, all examinations were performed in an enclosed stable with windows closed. Any undesirable artifacts present on the dorsal aspect of the forelimbs were removed by brushing one hour before the examination. All thermographic images were captured from the dorsal aspect of the forelimbs (Fig. 1) by the same operator, maintaining a consistent camera-to-subject distance of 1.5 meters for all images (19). Temperature analysis was conducted manually by a single examiner using IRBIS 3 Professional software (InfraTec, Dresden, Germany). For each session, the mean temperature (Avg), standard deviation (SD), minimum temperature (Min), and maximum temperature (Max) were recorded. Measurements were taken from six regions of interest (ROIs) on the dorsal aspect of the third metacarpal bone of both forelimbs: laterally (L1 and L6), centrally (L2 and L5), and medially (L3 and L4). Vertical reference lines were utilized to ensure measurement accuracy and minimize errors.

**Orthopedic examination.** The orthopedic examination was conducted following the thermographic assessment and included palpation and lameness scoring. The palpation examination aimed to detect swelling, pain, or increased heat on the dorsal surface of the third metacarpal bones. Both



**Fig. 1.** A representative thermographic image of the distal forelimbs from the dorsal aspect, taken before high-intensity laser therapy of the horse from high intensity laser therapy-treated group and control group. Symmetrical regions of interest (ROIs) were analyzed on both forelimbs from the dorsal perspective. The examined areas included: L1 and L6 – lateral regions of the right third metacarpal bone, L2 and L4 – medial regions of the third metacarpal bone, and L3 and L5 – central regions of the right third metacarpal bone. The average temperature was measured across these six ROIs (L1-L6) in the third metacarpal bones of both the left and right forelimbs

forelimbs were palpated in a weight-bearing position from proximal to distal and in a non-weight-bearing position from distal to proximal (15). Physical evidence of pain was scored based on horse response to dorsal metacarpal surface palpation. The pain scale employed in this study was modified from a previous method (7). Response was scored as follows:

- no reaction to palpation – no pain, painless;
- avoidance, resistance to palpation, or forelimb withdrawal – pain.

If changes on the dorsal surface of the third metacarpal bone indicated pain, the examination was considered positive; however, if the forelimb showed no pain response, it was classified as painless. In addition, swelling on the dorsal surface of the third metacarpal bone was evaluated by palpation and visual inspection. The severity of swelling and the associated pain response were recorded based on the examiner's subjective clinical assessment, and the presence of swelling in this region was considered a supportive clinical indicator of DMD.

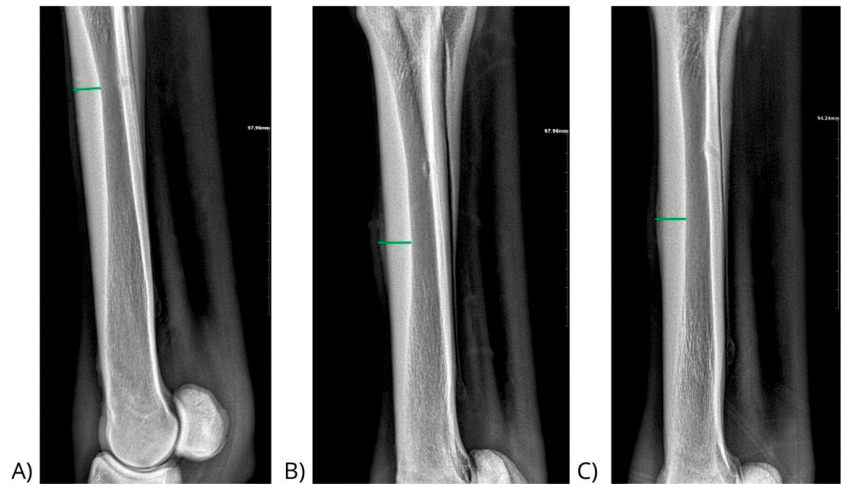
Lameness was assessed using the 5-point lameness scale established by the American Association of Equine Practitioners (2, 23). The visual lameness examination was conducted on a hard surface, evaluating the horses in a straight-line walk and trot, as well as during lunging in both left and right directions. All lameness assessments were performed by the same veterinarian to ensure consistency.

**Radiographic examination.** Radiological examinations were performed using a digital radiography system consisting of a meX + 20 BT lite generator (Medical ECONECT, Oberhausen, Germany) and a DR detector PRIMOS 1210T MOD (Vieworks, Gwanyang-dong, Anyang-si, Gyeonggi-do, Republic of Korea). Each horse underwent radiographic

imaging of the third metacarpal bone, with lateromedial projections taken immediately after the orthopedic examination. Each horse had a radiographic examination of its left and right third metacarpal bone taken in a latero-medial projection by the one examiner before and after HILT, including tube voltage 66 kVp and tube current 1.8 mAs, and a focal distance of 1 m between the processor and generator. A strict 1-meter distance between the X-ray source and the detector was maintained to prevent geometric distortion of the imaged structures and ensure maximal objectivity in measuring cortical bone thickness. During the procedure, the body weight of the examined horses was evenly distributed across both forelimbs. The detector was positioned laterally between the forelimbs, while the generator was positioned so that the emitted light was directed perpendicularly onto the detector. The entire length of the third metacarpal bone was encompassed within the field of view of both the processor and the generator. For each horse, dorsal cortical thickness and the presence of periosteal reaction were measured by the same examiner (Fig. 2) (44) using VXvue software (Vieworks, Gwanyang-dong, Anyang-si, Gyeonggi-do, Republic of Korea). Figure 2 illustrates representative radiographic images obtained during the monitoring period, including examinations performed prior to HILT therapy and after completion of the treatment protocol. Measurements were taken at the widest point of the cortical layer thickness in individual horses.

**Blood sample collection.** Before blood sample collection, the blood collection site on each horse was disinfected using a gauze pad soaked in 70% isopropyl alcohol. A sterile BD Vacutainer® system with a 20 G ½" needle was used for blood collection. Blood samples were obtained via puncture of the left external jugular vein. Blood samples were collected in three specialized test tubes: K2-EDTA tubes for determining white blood cell (WBC) levels, clot activator tubes for measuring serum amyloid A (SAA), and sodium citrate (3.2%) tubes for fibrinogen analysis. The collected samples were stored under cool conditions and transported to the Polish Veterinary Laboratory (VetLab), where they were analyzed within one hour of collection. Hematological parameters were assessed using a Sysmex XN-1000 hematology analyzer (Sysmex America, Inc., Lincolnshire, IL, USA), with WBC levels expressed as  $10^9/L$ . SAA concentrations were determined via an immunoturbidimetric assay using an AU680/AU5800 analyzer, with normal SAA values defined as  $< 2.00$  mg/L. Fibrinogen levels were measured using the Clauss method with a Bio-Ksel 6100 analyzer, with reference values ranging from 1.00 to 3.30 g/L.

**HILT treatment.** HILT was administered using a Class 4 laser, Polaris HP S (ASTAR, Bielsko-Biala, Poland), which operates with two infrared wavelengths delivered simultaneously: 808 nm (AlGaAs laser with an output power of 8 W) and 980 nm (InGaAs/AlGaAs laser with an output power of 10 W). The energy density was  $10.0$  J/cm<sup>2</sup> at a power of 3.50 W, with a pulse mode frequency of 50.00 Hz, and total energy dose: 1000 J. The HILT protocol was developed in



**Fig. 2.** Example of radiographic images of the third metacarpal bone in a lateral-medial projection A) radiograph obtained during routine monitoring examination prior to the onset of DMD, with the cortical bone thickness indicated (green line). B) Radiograph of a forelimb with clinical DMD obtained on day 0 of High-Intensity Laser Therapy (HILT), with the cortical bone thickness and periosteal measurement indicated (green line). C) Radiograph of a forelimb with clinical DMD obtained after completion of HILT therapy, with the cortex and periosteal thickness measurement indicated (green line)

accordance with the standard parameters used in the treatment of tendons and bones (17, 20, 22, 58, 60). The laser was applied with continuous movement of the applicator to prevent thermal effects. All horses from HILT-treated group received identical laser treatment parameters following a standardized protocol designed to allow tendons and surrounding tissues adequate time to respond to the treatment. The duration of each HILT application and the total energy dose were dependent on the treatment area and were automatically calculated by the device using the manufacturer's algorithm. Laser treatment was performed on weight-bearing forelimbs and hindlimbs, specifically targeting the dorsal aspect of the right and left third metacarpal bones. The treatment area measured 100 cm<sup>2</sup>, and the total irradiation time was 5 minutes 57 seconds. Each forelimb underwent an HILT procedure. None of the horses had their forelimb coats shaved prior to treatment. The laser probe, equipped with a spacer, was positioned perpendicular to the treatment area, and a contact technique was employed to minimize light scattering. All laser treatment sessions were conducted by the same examiner. The total duration of the HILT treatment was 15 days.

**Statistical analysis.** All statistical analyses of the test results were performed using STATISTICA v. 13.3 (TIBCO Software Inc., Palo Alto, CA, USA), JASP (Version 0.19.3, JASP Team 2024), and Microsoft Excel. To assess differences in mean body surface temperatures along specific metacarpal lines, one-way ANOVA was conducted with "line location" as the fixed factor. In subsequent analyses, average body surface temperature (Tavg) was used as a representative index. For comparisons between the HILT-treated and control groups, Welch's t-test was applied due to unequal variances (confirmed by Levene's test). When data deviated significantly from normality, Box-Cox transformation was applied to stabilize variance and approximate normal distribution prior to factorial ANOVA. This test assessed

the interaction effect between the HILT-treated group and session on the temperature index ( $\Delta T_{trans}$ ).

Additionally, since no significant differences were found, the mean value of the three lines (Tavg) was adopted as the thermal indicator for each forelimb in subsequent analyses.

To account for individual differences among the examined horses and for fluctuations in ambient temperature across successive sessions, the analysis focused on the difference in average temperature between the forelimb with DMD and the healthy forelimb for each of the 16 horses:

$$\Delta T_{avg} = T_{avgDMD\text{-affected forelimb}} - T_{avgHealthy forelimb}$$

As the variances of  $\Delta T_{avg}$  were not equal in every treatment session (verified use of Levene's test), Welch's t-test was used for comparing the means of two independent groups (HILT-treated group vs Control group). Additionally, the primary endpoint for thermographic assessment was the difference in temperature change between the DMD-affected and contralateral healthy forelimbs in the HILT-treated group (with HILT) compared with the control group (without HILT). Statistical analysis was performed using a repeated-measures ANOVA (or mixed-effects model, depending on your method), with treatment group and session as factors.

Pain assessment data were analyzed using Pearson's chi-square test to evaluate independence between categorical variables across sessions. In the case of lameness grades, odds ratios (OR) with 95% confidence intervals were calculated. In radiographic examination, both independent and paired Student's t-tests were used to compare dorsal cortical thickness between and within groups. For leukocytes, fibrinogen and SAA, Student's t-test or Wilcoxon signed-rank test was applied, depending on the distribution characteristics, to assess intra- and inter-group differences.

The correlation between body surface temperature and the thickness of the cortex was also examined, as well as the correlation between pain during palpation and the degree of lameness.

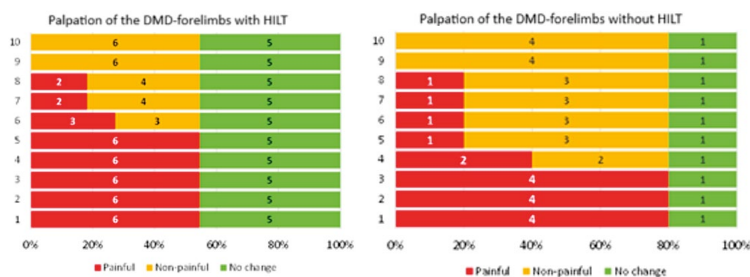
## Results and discussion

The difference in temperature change between the forelimb affected by DMD and the healthy forelimb in the HILT-treated group and the control group is presented in Table 1.

In both groups, the temperature differences between affected and healthy forelimbs were consistently small across all sessions, ranging from  $-0.2$  to  $0.4^\circ\text{C}$  in the HILT-treated group and  $-0.4$  to  $0.7^\circ\text{C}$  in the control group. No session in either group showed a statistical difference between T(D) and T(H) (all  $p > 0.05$ ). Comparison between groups (HILT vs. control): The  $\Delta T$  values between the HILT and control groups did not differ significantly in any session (all p-values ranging from 0.151 to 0.940).

The number of forelimbs with pain on the dorsal surface of the metacarpus, in forelimbs in HILT-treated group and control group, across 10 measurement sessions is illustrated in Figure 3. In both horse groups, pain was observed up to the 8<sup>th</sup> session.

Before treatment began (Session 1), pain was present in 11 forelimbs; however, after the 10<sup>th</sup> treatment session, all horses were pain-free. The results of the



**Fig. 3.** The table shows the number of forelimbs diagnosed with dorsal metacarpal disease (DMD) in both the high-intensity laser therapy (HILT)-treated and control groups, along with changes in pain responses during palpation across consecutive measurement sessions

**Tab. 1.** Body surface temperature difference ( $\Delta T$ ) between the dorsal metacarpal disease-affected forelimb (D) and the healthy contralateral forelimb (H) in horses from the HILT-treated group (with HILT) and the control group (without HILT)

| Session | Group with HILT<br>N = 11 |                  |            | Group without HILT<br>N = 5 |                  |            | $\Delta T$ with HILT<br>vs without HILT<br>p-value |
|---------|---------------------------|------------------|------------|-----------------------------|------------------|------------|--|
|         | Forelimb<br>T(D)          | Forelimb<br>T(H) | $\Delta T$ | Forelimb<br>T(D)            | Forelimb<br>T(H) | $\Delta T$ |  |
| 1       | 32.2 (1.9)                | 32.0 (2.2)       | 0.2 (0.5)  | 30.2 (0.9)                  | 29.8 (1.3)       | 0.3 (0.6)  | 0.675  |
| 2       | 28.7 (5.2)                | 28.6 (5.3)       | 0.1 (0.6)  | 26.9 (2.9)                  | 26.7 (3.5)       | 0.2 (1.3)  | 0.731  |
| 3       | 26.9 (5.0)                | 26.8 (5.1)       | 0.1 (0.5)  | 25.7 (5.0)                  | 25.6 (4.8)       | 0.1 (0.7)  | 0.940  |
| 4       | 29.8 (3.6)                | 29.4 (3.9)       | 0.4 (1.2)  | 27.7 (0.7)                  | 27.0 (1.7)       | 0.7 (1.6)  | 0.680  |
| 5       | 30.3 (3.0)                | 30.4 (3.2)       | -0.1 (0.7) | 27.5 (2.1)                  | 27.4 (2.7)       | 0.1 (0.9)  | 0.654  |
| 6       | 31.2 (1.6)                | 31.1 (1.4)       | 0.1 (0.8)  | 29.8 (2.8)                  | 30.2 (2.8)       | -0.4 (0.3) | 0.151  |
| 7       | 31.0 (1.6)                | 30.7 (1.9)       | 0.2 (1.1)  | 28.2 (1.8)                  | 28.3 (1.9)       | -0.1 (0.2) | 0.486  |
| 8       | 30.1 (2.2)                | 29.8 (2.5)       | 0.3 (1.2)  | 29.3 (2.7)                  | 29.1 (3.2)       | 0.2 (0.6)  | 0.846  |
| 9       | 29.1 (3.6)                | 29.1 (3.3)       | -0.1 (0.8) | 28.8 (3.1)                  | 28.7 (3.9)       | 0.1 (0.8)  | 0.726  |
| 10      | 28.5 (3.8)                | 28.7 (3.5)       | -0.2 (0.8) | 29.3 (3.2)                  | 29.6 (2.6)       | -0.3 (0.7) | 0.777  |

Explanations: The bodysurface temperature measured at the level of the third metacarpal bone ( $^\circ\text{C}$ ); N – number of forelimbs;  $\Delta T$  – temperature difference between forelimbs ( $^\circ\text{C}$ ).

palpation tests suggest that HILT treatment could have been concluded after the 8<sup>th</sup> session (Tab. 2).

In the both groups of 16 horses, a total of 160 lameness evaluations were conducted over 10 sessions.

**Tab. 2. Number and percentage of forelimbs affected and unaffected by dorsal metacarpal disease (DMD) in HILT-treated group (with HILT) and control group (without HILT), categorized based on pain response during palpation**

| Session 1     | Palpation of the forelimb with DMD |              |         | Palpation of the forelimb without DMD |              |         |
|---------------|------------------------------------|--------------|---------|---------------------------------------|--------------|---------|
|               | with HILT                          | without HILT | p-value | with HILT                             | without HILT | p-value |
| Painful (1)   | 6 (37.5%)                          | 4 (25.0%)    | 0.33    | 1 (6.3%)                              | 0 (0.0%)     | 0.49    |
| No change (0) | 5 (31.3%)                          | 1 (6.3%)     |         | 10 (62.5%)                            | 5 (31.3%)    |         |

| Session 10      | Palpation of the forelimb with DMD |              |         | Palpation of the forelimb without DMD |              |         |
|-----------------|------------------------------------|--------------|---------|---------------------------------------|--------------|---------|
|                 | with HILT                          | without HILT | p-value | with HILT                             | without HILT | p-value |
| Painful (1)     | 0 (0.0%)                           | 0 (0.0%)     | 0.33    | 0 (0.0%)                              | 0 (0.0%)     | 1.00    |
| Non-painful (0) | 6 (37.5%)                          | 4 (25.0%)    |         | 0 (0.0%)                              | 0 (0.0%)     |         |
| No change (0)   | 5 (31.3%)                          | 1 (6.3%)     |         | 11 (68.7%)                            | 5 (31.3%)    |         |

Explanations: Painful – forelimb with positive response to palpation; Non-painful – forelimb that changed from a positive response to palpation during the examination to a negative response; No change – forelimb with negative response to palpation.

**Tab. 3. The number (or percentage) of horses in the high intensity laser therapy (HILT)-treated group (with HILT) and the control group (without HILT), showing different HILT treatment protocols and lameness grades throughout the treatment**

| Degree lameness | With HILT<br>N = 110 | Without HILT<br>N = 50 | p-value                               | OR [95% CI]       |
|-----------------|----------------------|------------------------|---------------------------------------|-------------------|
| 0               | 105 (93.6%)          | 41 (82.0%)             | $\chi^2 = 6.74$<br>df = 2<br>p = 0.03 | 1.00 (ref)        |
| I               | 1 (0.9%)             | 0 (0.0%)               |                                       | 1.18 [0.05; 29.6] |
| II              | 6 (5.5%)             | 9 (18.0%)              |                                       | 0.26 [0.09; 0.78] |

**Tab. 4. The number (or percentage) of horses in the high intensity laser therapy (HILT)-treated group (with HILT) and the control group (without HILT), showing different HILT treatment protocols and lameness grades during the 1<sup>st</sup> and 4<sup>th</sup> treatment sessions**

| Session | Degree lameness | With HILT<br>N = 11 | Without HILT<br>N = 5 | p-value | OR [95% CI]       |
|---------|-----------------|---------------------|-----------------------|---------|-------------------|
| 1       | II              | 2 (18.2%)           | 3 (60.0%)             | 0.24    | 0.15 [0.01; 1.56] |
|         | 0               | 9 (81.8%)           | 2 (40.0%)             |         | 1.00 (ref)        |
| 4       | I               | 1 (9.1%)            | 0 (0.0%)              | 1.00    | 1.57 [0.05; 45.4] |
|         | 0               | 10 (90.9%)          | 5 (100.0%)            |         | 1.00 (ref)        |

**Tab. 5. Total number (percentage) of palpation scores and lameness scores during 10 laser treatment sessions in high intensity laser therapy treated group and control group**

| Lameness | Palpation examination results |                    |                     | Test result                            |
|----------|-------------------------------|--------------------|---------------------|--|
|          | Pain<br>N = 38                | Painless<br>N = 22 | No change<br>N = 50 |  |
| II°      | 18 (100.0%)                   | 0 (0.0%)           | 0 (0.0%)            | $\chi^2 = 58.2$<br>df = 4<br>p < 0.001 |
| I°       | 6 (100.0%)                    | 0 (0.0%)           | 0 (0.0%)            |  |
| 0°       | 14 (16.3%)                    | 22 (25.6%)         | 50 (58.1%)          |  |

Explanations: 0° – Lameness not perceptible under any circumstances; I° – Lameness that is difficult to observe and is not consistently apparent, regardless of circumstances; II° – Lameness that is difficult to observe at a walk or when trotting in a straight line, but consistently apparent under certain circumstances.

The horses were randomly assigned to their respective groups. The degree of lameness in both groups was grade II. The control group did not receive any treatments. Assessments for all sessions in groups differing in HILT treatment are presented in Table 3.

A significant association was observed between HILT treatment and the degree of lameness (p = 0.034). In the HILT-treated group, grade II lameness was nearly four times lower compared to horses in the control group (OR = 0.26, 1/OR = 3.84). Lameness was observed only up to the 4<sup>th</sup> treatment session in both group (Tab. 4).

A strong correlation was observed between the pain during the palpation examination and the degree of lameness. Horses with grade I and II lameness were 100% non painful on palpation. Pain not related to lameness was observed in only 16.3% of studies (Tab. 5). A correlation was observed between the number of treatments and the results of orthopedic examination (reduction of metacarpal pain/reduction of lameness).

The dorsal cortical thickness of both groups with DMD and healthy forelimbs was significantly greater; however, no significant effect of HILT on cortex thickness was observed (Tab. 6). The table shows that from session 6 onward, cortex thickness (CT) in the HILT group was significantly higher than in the control group for both affected and healthy forelimbs. However, within individual horses, no significant differences were observed between DMD-affected and healthy forelimbs in any session.

Additionally, no significant correlation was observed between the change in body surface temperature and cortex thickness (p > 0.05) both in the HILT-treated group and control group. Before the first therapeutic session (Session 1) and after the last session (Session 10), leukocyte and fibrinogen levels were assessed in all horses (Tab. 7). The analysis revealed a significant decrease in leukocyte levels in the HILT-treated group (from 9.51 to 8.68 × 10<sup>3</sup>/mL; p = 0.02) compared to baseline values. In this study, baseline values were established based on blood test results obtained from all horses before the first therapeutic session (Session 1). In the HILT group, comparisons focused on changes in leukocyte counts within the same group relative to the pre-treatment baseline. In the control group, changes in parameters such as fibrinogen levels were similarly assessed against the values obtained prior to the first session.

In the control group, a significant reduction in fibrinogen levels was observed (from 1.55 to 1.39 g/L;

**Tab. 6.** Statistical results (mean; SD) of the dorsal cortical thickness (CT) of the forelimb with dorsal metacarpal disease (D) and the healthy forelimb (H) in High-Intensity Laser Therapy (HILT)-treated horse (with HILT) and in the control group (without HILT) in 1-10 sessions and the results of significance tests

| Session | Dorsal cortical thickness (mm) | Group of horses     |                        | With HILT vs. Without HILT |
|---------|--------------------------------|---------------------|------------------------|----------------------------|
|         |                                | with HILT<br>N = 11 | without HILT<br>N = 15 |                            |
| 1       | CT(D), mean (SD)               | 12.6 (1.0)          | 12.3 (1.0)             | p = 0.527                  |
|         | CR(H), mean (SD)               | 12.6 (1.2)          | 12.6 (1.3)             | p = 0.950                  |
|         | CT(D) vs. PT(H)                | p = 0.799           | p = 0.264              | ×                          |
| 2       | CT(D), mean (SD)               | 12.5 ± 0.9          | 12.4 ± 0.9             | p = 0.734                  |
|         | CR(H), mean (SD)               | 13.0 ± 1.0          | 12.5 ± 1.1             | p = 0.409                  |
|         | CT(D) vs. PT(H)                | p = 0.270           | p = 0.381              | ×                          |
| 3       | CT(D), mean (SD)               | 12.5 ± 0.5          | 12.5 ± 0.8             | p = 0.984                  |
|         | CR(H), mean (SD)               | 12.2 ± 1.0          | 12.6 ± 1.0             | p = 0.439                  |
|         | CT(D) vs. PT(H)                | p = 0.567           | p = 0.571              | ×                          |
| 4       | CT(D), mean (SD)               | 13.2 ± 1.2          | 12.7 ± 1.1             | p = 0.323                  |
|         | CR(H), mean (SD)               | 13.2 ± 0.8          | 12.8 ± 1.3             | p = 0.552                  |
|         | CT(D) vs. PT(H)                | p = 0.924           | p = 0.482              | ×                          |
| 5       | CT(D), mean (SD)               | 13.9 ± 1.4          | 12.8 ± 1.2             | p = 0.109                  |
|         | CR(H), mean (SD)               | 14.2 ± 1.3          | 13.0 ± 1.2             | p = 0.056                  |
|         | CT(D) vs. PT(H)                | p = 0.551           | p = 0.603              | ×                          |
| 6       | CT(D), mean (SD)               | 14.4 ± 1.2          | 12.9 ± 1.2             | p = 0.017                  |
|         | CR(H), mean (SD)               | 14.9 ± 1.5          | 13.1 ± 1.5             | p = 0.027                  |
|         | CT(D) vs. PT(H)                | p = 0.456           | p = 0.359              | ×                          |
| 7       | CT(D), mean (SD)               | 14.0 ± 1.1          | 12.7 ± 1.2             | p = 0.030                  |
|         | CR(H), mean (SD)               | 14.6 ± 1.5          | 12.7 ± 1.1             | p = 0.007                  |
|         | CT(D) vs. PT(H)                | p = 0.405           | p = 0.964              | ×                          |
| 8       | CT(D), mean (SD)               | 14.4 ± 1.4          | 13.0 ± 1.2             | p = 0.036                  |
|         | CR(H), mean (SD)               | 15.5 ± 1.0          | 12.9 ± 1.2             | p < 0.001                  |
|         | CT(D) vs. PT(H)                | p = 0.122           | p = 0.948              | ×                          |
| 9       | CT(D), mean (SD)               | 14.5 ± 1.4          | 13.0 ± 1.3             | p = 0.043                  |
|         | CR(H), mean (SD)               | 16.1 ± 1.4          | 13.3 ± 1.3             | p = 0.001                  |
|         | CT(D) vs. PT(H)                | p = 0.029           | p = 0.183              | ×                          |
| 10      | CT(D), mean (SD)               | 15.0 ± 1.4          | 13.2 ± 1.4             | p = 0.018                  |
|         | CR(H), mean (SD)               | 16.1 ± 2.0          | 13.7 ± 1.1             | p = 0.004                  |
|         | CT(D) vs. PT(H)                | p = 0.059           | p = 0.157              | ×                          |

Explanations: CT(D) – the dorsal cortical thickness of the forelimb with dorsal metacarpal disease; CT(H) – the dorsal cortical thickness of the healthy forelimb, N – number of forelimbs.

**Tab. 7.** Leukocyte and fibrinogen levels in high intensity laser therapy (HILT)-treated group (with HILT) and control group (without HILT), measured during the 1<sup>st</sup> and 10<sup>th</sup> treatment sessions, along with significance test results

| Session | Leukocytes (× 10 <sup>3</sup> /mL) |                       |                   | Fibrinogen (g/L)      |                       |                   |
|---------|------------------------------------|-----------------------|-------------------|-----------------------|-----------------------|-------------------|
|         | with HILT                          | without HILT          | p                 | with HILT             | without HILT          | p                 |
| 1       | 9.51 ± 1.61                        | 9.65 ± 1.88           | 0.89 <sup>a</sup> | 1.46 [1.38; 1.63]     | 1.55 [1.51; 1.90]     | 0.17 <sup>c</sup> |
| 10      | 8.68 ± 0.92                        | 9.68 ± 2.76           | 0.29 <sup>a</sup> | 1.48 [1.32; 1.63]     | 1.39 [1.26; 1.51]     | 0.61 <sup>c</sup> |
|         | p = 0.02 <sup>b</sup>              | p = 0.98 <sup>b</sup> | ×                 | p = 0.65 <sup>d</sup> | p = 0.04 <sup>d</sup> | ×                 |

p = 0.04). No significant interaction between HILT treatment and session duration was found.

Based on thermographic, radiographic, orthopedic examinations, and blood results, we monitored the effectiveness of HILT in the treatment of DMD in 2-year-old Thoroughbreds. Previous studies have demonstrated the therapeutic benefits of HILT in various orthopedic conditions in human medicine (23, 53). However, this remains an expanding area within treatment, with only a limited number of publications addressing the effectiveness of HILT for musculoskeletal injuries in veterinary medicine (41, 58). To our knowledge, this is the first study to document the clinical use of laser light treatment via HILT as a primary treatment for DMD on the dorsal aspect of the third metacarpal bone in horses.

Previous studies have validated the use of thermographic examination as an effective diagnostic tool for detecting DMD (44, 50). Due to its ability to visualize superficial heat, thermography enables the detection of subclinical inflammation, allowing for early diagnosis of DMD before clinical signs appear (44). Our study aimed to investigate the changes in body surface temperature following HILT treatment for DMD, a subject not previously explored in the literature. No session in either group showed a statistical difference between T(D) and T(H) (all p > 0.05), suggesting that, within individual horses, the body surface temperature of the affected limb remained comparable to that of the healthy limb throughout the study.

Previous studies have described the analgesic effects of HILT on affected soft tissues, which resulted in a reduction in the degree of lameness (38). In our study, we observed a strong correlation between the presence of pain starting from the 6<sup>th</sup> session and the degree of lameness from the 5<sup>th</sup> session of HILT treatment in the group of horses with DMD. Zielińska et al. (58) observed the effects of HILT in 11 horses with radiological signs of bone spavin. Their study demonstrated that HILT treatment led to a reduction in joint pain, which subsequently contributed to a decrease in visual lameness. Based on the observed findings and previous literature, HILT may potentially reduce pain in horses with DMD. This analgesic effect could, in turn, lead to a decrease in the degree of lameness, suggesting an improvement in overall forelimb function and animal comfort.

Moreover, the thickness of the cortex did not show significant changes throughout the treatment sessions. Radiological examination remains one of the most crucial tools for detecting remodeling of the periosteal surface. Finsen et al. (13) noted that radiography can identify DMD when there is at least a 30% increase in bone mineral density. This study is the first to measure changes in cortex thickness during HILT treatment. Despite the lack of significant changes in cortex thickness, the examination revealed a flatten-

ing of the bone remodeling on the surface of the third metacarpal bone, suggesting that periosteal new bone formation had ceased. A periosteal reaction typically results from negative stimuli, such as trauma, inflammation, or infection affecting the cortical bone (39). Stress fractures often show subtle periosteal reactions in areas of pain or trauma, and in the case of DMD, a periosteal reaction is also commonly observed (33). However, our study did not demonstrate a role of HILT in inhibiting the remodeling process on the surface of the third metacarpal bone. Nonetheless, this study may open new avenues for research that could confirm the therapeutic effects of HILT on bone tissue.

Leukocytes, fibrinogen, and SAA are among the most commonly used blood parameters to detect inflammatory processes within the body (3, 11). These parameters are frequently employed as monitoring factors during the training of young Thoroughbreds. Additionally, leukocytes and SAA have been measured in horses with orthopedic injuries in various studies (52). In the present study, we observed a significant decrease in the leukocyte levels between the 1<sup>st</sup> and 10<sup>th</sup> session of laser in HILT-treated group. Furthermore, a significant reduction in fibrinogen levels was noted in the control group. Notably, no increase in SAA levels was observed in either group. Anhold et al. (3) demonstrated that WBC count and other inflammatory parameters are correlated, with fibrinogen and SAA showing the greatest concordance among the top 15% of values. This correlation supports the appropriateness of selecting these parameters to measure the anti-inflammatory effects of HILT in our study. These patterns suggest that natural variation in blood parameters, including biochemical markers, may obscure values that would typically indicate pathological conditions (3). This could explain the observed reduction in fibrinogen levels in the group of DMD horses without HILT. The significant decrease in leukocyte levels, however, clearly indicates a reduction in the inflammatory process. We concluded that the concentration of SAA is not an ideal parameter for monitoring the progress of HILT, as its levels rise as early as 6 hours following the stimulation of inflammatory factors, such as tissue injury. When the inflammation resolves, SAA levels drop within 12 hours (52). In contrast, fibrinogen levels increase above normal within 24-48 hours and remain elevated for up to 10 days, making it a more reliable indicator of the degree of inflammation compared to SAA (10). There were no significant differences between the other parameters. Moreover, the mean SAA concentration within the first 4 days after muscle and tendon injuries was significantly higher compared to bone fractures, dorsal metacarpal disease or joint trauma (10). Additionally, body surface temperature can be used to monitor chronic inflammation, particularly when structural changes in bone tissue are evident due to advanced disruption. In both groups of horses, body surface temperature did not necessarily correlate with the level of changes in the third metacarpal bone.

There are several limitations to the current study, including the relatively small number of horses with and without DMD. Probably a reasonable and achievable goal for medium effects would be ~ 3-35 horses in total. Unfortunately, it is difficult to predict how many horses will develop DMD in a given season. Additionally, each examination was performed at the same time of day, although the weather conditions outside varied, which may also be a limitation of our study. To minimize the impact of external factors, the environment was prepared in accordance with our previous studies. Moreover, we believe that conducting additional radiological examinations and blood collections would provide more comprehensive data on the therapeutic effects of HILT.

A significant decrease in leukocyte levels was observed in the HILT-treated group, and a decrease in fibrinogen in the control group, both values remained within physiological norms. Although all included horses were free of other diagnosed orthopedic conditions, and previous studies suggest elevated leukocyte and fibrinogen levels may accompany DMD related inflammation (38, 39), our results do not strongly confirm these parameters as reliable indicators of HILT efficacy.

Another limitation of the present study is that the clinical evaluation was performed only on a hard surface. Including lameness assessment on a soft surface in future studies could provide a more comprehensive evaluation of potential involvement of tendons and ligaments and allow a clearer differentiation of the effects of HILT on bone structures versus the surrounding soft tissues.

The present study does not allow for conclusive determination that HILT accelerates healing or shortens treatment time in Thoroughbred racehorses with DMD. Nevertheless, the data suggest that HILT, applied as the sole treatment intervention, may alleviate clinical signs, including pain and lameness, when compared to horses withdrawn from training but not receiving treatment. These preliminary findings warrant further investigation, with expanded evaluation encompassing bone tissue and additional joints, to rigorously assess the therapeutic potential of HILT in equine musculoskeletal treatment.

## References

1. Alayat M. S. M., Atya A., Ali M. M. E., Shosha T. M.: Long-term effect of high-intensity laser therapy in the treatment of patients with chronic low back pain: A randomized blinded placebo-controlled trial. *Lasers Med. Sci.* 2013, 29, 1065-1073.
2. *American Association of Equine Practitioners: Guide to Veterinary Services for Horse Shows.* 7<sup>th</sup> ed., AAEP: Lexington, KY, USA 1999.
3. Anhold H., Candon R., Chan D. S., Amos W.: A comparison of elevated blood parameter values in a population of Thoroughbred racehorses. *J. Equine Vet. Sci.* 2014, 34, 651-655.
4. Barrelet A., Ricketts S.: Haematology and blood biochemistry in the horse: a guide to interpretation. In *Pract.* 2002, 24, 318-327.
5. Baxter G. M.: Adams and Stashak's lameness in horses. 6<sup>th</sup> ed., Wiley-Blackwell, Hoboken (NJ) 2011, p. 93.
6. Brown A. W., Weber D. C.: Physical agent modalities, [in:] *Physical Medicine and Rehabilitation*; Braddom R. L., ed., W. B. Saunders: London, UK 2000, p. 440-458.
7. Bussièrès G., Jacques C., Lainay O., Beauchamp G., Leblond A., Cadoré J. L., Desmaizères L. M., Cuvellez S., Troncy E.: Development of a composite orthopaedic pain scale in horses. *Res. Vet. Sci.* 2008, 85, 294-306.

8. Conforti M., Fachinetti G. P.: High power laser therapy treatment compared to simple segmental physical rehabilitation in whiplash injuries. *Muscles Ligaments Tendons J.* 2013, 3, 106.
9. Couch S., Nielsen B.: A review of dorsal metacarpal disease bucked shins in the flat racing horse: prevalence, diagnosis, pathogenesis, and associated factors. *J. Dairy Vet. Anim. Res.* 2017, 5, 228-236.
10. Crisman M. V., Scarratt W. K., Zimmerman K. L.: Blood proteins and inflammation in the horse. *Vet. Clin. N. Am.* 2008, 24, 285-297.
11. Eckersall P. D., Bell R.: Acute phase proteins: Biomarkers of infection and inflammation in veterinary medicine. *Vet. J.* 2010, 185, 23-27.
12. Ezzati K., Laakso E. L., Salari A., Hasannejad A., Fekrazad R., Aris A.: The beneficial effects of high-intensity laser therapy. *J. Lasers Med. Sci.* 2020, 11, 81.
13. Finsen V., Andra S.: Accuracy of visually estimated bone mineralisation in routine radiographs of the lower extremity. *Skelet. Radiol.* 1988, 17, 270-275.
14. Fiore P., Panza F., Cassatella G., Russo A., Frisardi V., Solfrizzi V., Ranieri M., Di Teo L., Santamato A.: Short-term effects of high-intensity laser therapy versus ultrasound therapy in the treatment of low back pain: A randomized controlled trial. *Eur. J. Phys. Rehabil. Med.* 2011, 47, 367-373.
15. Firth E. C., Rogers C. W., Double M., Jopson N. B.: Musculoskeletal responses of 2-year-old Thoroughbred horses to early training. 6. Bone parameters in the third metacarpal and third metatarsal bones. *N. Zeal. Vet. J.* 2005, 53, 101-112.
16. Fortuna D.: High-intensity laser therapy for the equine patient, [in:] *Laser Therapy in Veterinary Medicine*; Wiley, 2017, p. 415-421.
17. Godlewska M., Soroko M., Zielińska P.: Assessment of vein diameter and body surface temperature after high-intensity laser therapy (HILT) on the tarsal joint in healthy horses. *J. Equine Vet. Sci.* 2020, 93, 103198.
18. Guerra F. D. R., Vieira C. P., Almeida M. S., Oliveira L. P., de Aro A. A., Pimentel E. R.: LLLT improves tendon healing through increase of MMP activity and collagen synthesis. *Lasers Med. Sci.* 2013, 28, 1281-1288.
19. Howell K., Dudek K., Soroko M.: Thermal camera performance and image analysis repeatability in equine thermography. *Infrared Phys. Technol.* 2020, 110, 103447.
20. Jaafar S. E., Al-Bayti A. A., Abdullah S. I.: Using short term of high power laser therapy in horse's tendon injuries. *Arch. Razi Inst.* 2021, 76, 1437-1444.
21. Kheshie A. R., Alayat M. S. M., Ali M. M. E.: High-intensity versus low-level laser therapy in the treatment of patients with knee osteoarthritis: A randomized controlled trial. *Lasers Med. Sci.* 2014, 29, 1371-1376.
22. Kitiwong A., Issariyodom P., Pirunsan U., Na Lampang K., Rungsri P.: Superficial digital flexor tendinitis treatment using high-intensity laser therapy and therapeutic ultrasound in polo ponies. *Vet. Integr. Sci.* 2022, 20, 253-266.
23. LeJeune S., Jones J.: Prospective study on the correlation of positive acupuncture scans and lameness in 102 performance horses. *Am. J. Chin. Med.* 2014, 33-41.
24. Lievens P. C.: The effect of a combined HeNe and IR laser treatment on the regeneration of the lymphatic system during the process of wound healing. *Lasers Med. Sci.* 1991, 6, 193-199.
25. Lu Q., Yin Z., Shen X., Li J., Su P., Feng M., Shen Y.: Clinical effects of high-intensity laser therapy on patients with chronic refractory wounds: a randomised controlled trial. *BMJ open* 2021, 11 (7), e045866.
26. Mårdh A., Lund I.: High power Laser for treatment of Achilles tendinosis – a single blind randomized placebo controlled clinical study. *J. Lasers Med. Sci.* 2016, 7, 92.
27. Marcos R. L., Arnold G., Magnenet V., Rahouadj R., Magdalou J., Lopes-Martins R. A. B.: Biomechanical and biochemical protective effect of low-level laser therapy for Achilles tendinitis. *J. Mech. Behav. Biomed. Mater.* 2014, 29, 272-285.
28. Marcos R. L., Leal-Junior E. C. P., Arnold G., Magnenet V., Rahouadj R., Wang X., Lopes-Martins R. A. B.: Low-level laser therapy in collagenase-induced Achilles tendinitis in rats: Analyses of biochemical and biomechanical aspects. *J. Orthop. Res.* 2012, 30, 1945-1951.
29. Martig S., Chen W., Lee P. V., Whittin R. C.: Bone fatigue and its implications for injuries in racehorses. *Equine Vet. J.* 2014, 46, 408-415.
30. Morrice-West A. V., Hitchens P. L., Walmsley E. A., Tasker K., Lim S. L., Smith A. D., Whittin R. C.: Relationship between Thoroughbred workloads in racing and the fatigue life of equine subchondral bone. *Sci. Rep.* 2022, 12, 11528.
31. Nazari A., Moezy A., Nejadi P., Mazaherinezhad A.: Efficacy of high-intensity laser therapy in comparison with conventional physiotherapy and exercise therapy on pain and function of patients with knee osteoarthritis: a randomized controlled trial with 12-week follow up. *Lasers Med. Sci.* 2019, 34, 505-516.
32. Nunamaker D. M.: Bucked shins in horses. [in:] Burr D. B., Milgrom C. (ed.): *Musculoskeletal fatigue and stress fractures*; CRC Press, Boca Raton, Florida, USA 2001, p. 203-219.
33. Nunamaker D. M.: On bucked shins. *Proceedings of the 48<sup>th</sup> Annual Convention of the American Association of Equine Practitioners*. Orlando, FL, USA 2002, p. 76-89.
34. O'Sullivan C. B., Lumsden J. M.: Distal third metacarpal bone palmar cortical stress fractures in four Thoroughbred racehorses. *Equine Vet. Educ.* 2002, 14, 70-75.
35. Ordahan B., Karahan A. Y., Kaydok E.: The effect of high-intensity versus low-level laser therapy in the management of plantar fasciitis: a randomized clinical trial. *Lasers Med. Sci.* 2018, 33, 1363-1369.
36. Patterson-Kane J. C., Wilson A. M., Firth E. C., Parry D. A. D., Goodship A. E.: Exercise-related alterations in crimp morphology in the central regions of superficial digital flexor tendons from young Thoroughbreds: a controlled study. *Equine Vet. J.* 1998, 30, 61-64.
37. Peat F. J., Colbath A. C., Bentsen L. M., Goodrich L. R., King M. R.: In vitro effects of high-intensity laser photobiomodulation on equine bone marrow-derived mesenchymal stem cell viability and cytokine expression. *Photomed. Laser Surg.* 2018, 36, 83-91.
38. Pluim M., Martens A., Vanderperren K., Sarrazin S., Koene M., Luciani A., Van Weeren P., Delesalle C.: Short- and long term follow-up of 150 sports horses diagnosed with tendinopathy or desmopathy by ultrasonographic examination and treated with high-power laser therapy. *Res. Vet. Sci.* 2018, 119, 232-238.
39. Rana R. S., Wu J. S., Eisenberg R. L.: Periosteal reaction. *Am. J. Roentgenol.* 2009, 193, 259-272.
40. Riegel R. J., Godbold Jr. J. C.: *Laser Therapy in Veterinary Medicine: Photobiomodulation*. Wiley 2017.
41. Rushing J.: Does high-intensity laser therapy speed return to primary function in horses with suspensory ligament desmopathy? *Vet. Evid.* 2023, 8.
42. Santamato A., Solfrizzi V., Panza F., Tondi G., Frisardi V., Leggin B. G., Ranieri M., Fiore P.: Short-term effects of high-intensity laser therapy versus ultrasound therapy in the treatment of people with subacromial impingement syndrome: A randomized clinical trial. *Phys. Ther.* 2009, 89, 643-652.
43. Siriratna P., Ratanasutirant C., Manissorn T., Santiniyom N., Chira-Adisai W.: Short-term efficacy of high-intensity laser therapy in alleviating pain in patients with knee osteoarthritis: A single-blind randomised controlled trial. *Pain Res. Manag.* 2022, (1), 1319165.
44. Soroko M., Henklewski R., Filipowski H., Jodkowska E.: The effectiveness of thermographic analysis in equine orthopedics. *J. Equine Vet. Sci.* 2013, 33, 760-762.
45. Štiglic-Rogoznica N., Stamenković D., Frlan-Vrgoč L., Avancini-Dobrović V., Schnurrer-Luke Vrbančić T.: Analgesic effect of high intensity laser therapy in knee osteoarthritis. *Coll. Antropol.* 2011, 35 (2), 183-185.
46. Thabet A. A. E., Elsodany A. M., Battecha K. H., Alshehri M. A., Refaat B.: High-intensity laser therapy versus pulsed electromagnetic field in the treatment of primary dysmenorrhea. *J. Phys. Ther. Sci.* 2017, 29, 1742-1748.
47. Tinley B. V., Henson F. M.: Reliability and repeatability of thermographic examination and the normal thermographic image of the thoracolumbar region in the horse. *Equine Vet. J.* 2004, 36, 306-312.
48. Timilty S. M., Munn J., Abbott J. H., McDonough S., Hurley D. A., Baxter G. D.: Laser therapy in the treatment of Achilles tendinopathy: A pilot study. *Photomed. Laser Surg.* 2008, 26, 25-30.
49. Turlo A., Cywinska A., Czopowicz M., Witkowski L., Szarska E., Winnicka A.: Post-exercise dynamics of serum amyloid A blood concentration in thoroughbred horses classified as injured and non-injured after the race. *Res. Vet. Sci.* 2015, 100, 223-225.
50. Turner T. A.: Thermography as an aid to the clinical lameness evaluation. *Vet. Clin. N. Am., Equine Pract.* 1991, 7, 311-338.
51. Voronkov M. G., Motorina I. G., Iushkov G. G., Benemanski V. V., Rasulov M. M., Snisarenko T. A., Abzaeva K. A., Shukina O. G., Malishkina N. A.: Effect of laser radiation of infrared and red range on healing of burn wounds. *Dokl. Biochem. Biophys.* 2014, 456, 85-87.
52. Witkowska-Pilaszczyk O., Bąska P., Czopowicz M., Żmigrodzka M., Szczepaniak J., Szarska E., Winnicka A., Cywińska A.: Changes in serum amyloid A (SAA) concentration in Arabian endurance horses during first training season. *Animals* 2019, 9, 330.
53. Wyszynska J., Bal-Bocheńska M.: Efficacy of high-intensity laser therapy in treating knee osteoarthritis: a first systematic review. *Photomed. Laser Surg.* 2018, 36, 343-353.
54. Xie Y. H., Liao M. X., Lam F. M., Gu Y. M., Fernando W. H. A., Liao L. R., Pang M. Y.: The effectiveness of high-intensity laser therapy in individuals with neck pain: a systematic review and meta-analysis. *Phys. Ther.* 2023, 121, 23-36.
55. Young S., Bolton P., Dyson M., Harvey W., Diamantopoulos C.: Macrophage responsiveness to light therapy. *Lasers Surg. Med.* 1989, 9, 497-505.
56. Yasukawa A., Ohru H., Koyama Y., Nagai M., Takakuda K.: The effect of low reactive level laser therapy (LLLT) whit Heliun-neon laser on operative wound healing in a Rats model. *J. Vet. Med. Sci.* 2007, 69, 799-806.
57. Zati A., Valent A.: *Physical therapy: New technologies in rehabilitation medicine (translated to English)*. Edizioni Minerva Med. 2006, 162-185.
58. Zielińska P., Nicpoń J., Kielbowicz Z., Soroko M., Dudek K., Zaboriski D.: Effects of high intensity laser therapy in the treatment of tendon and ligament injuries in performance horses. *Animals* 2020, 10, 1327.
59. Zielińska P., Soroko M., Howell K., Godlewska M., Hildebrand W., Dudek K.: Comparison of the effect of high-intensity laser therapy (HILT) on skin surface temperature and vein diameter in pigmented and non-pigmented skin in healthy racehorses. *Animals* 2021, 11, 1965.
60. Zielińska P., Soroko-Dubrovina M., Dudek K., Ruzhanova-Gospodinova I. S.: A preliminary study of the influence of high intensity laser therapy (HILT) on skin surface temperature and longissimus dorsi muscle tone changes in Thoroughbred racehorses with back pain. *Animals* 2023, 13, 794.

Corresponding author: Karolina Śniegućka, DVM, PhD student, Institute of Animal Breeding, Wrocław University of Environmental and Life Sciences, Wrocław, Poland; e-mail: karolina.sniegućka@upwr.edu.pl