

Use of transcutaneous nerve stimulation, therapeutic ultrasound and low-level laser therapy methods in rats with experimental urinary incontinence

© MERAL KARAKOÇ¹, © NAZAN BAKSI², © ZELAL KARAKOÇ², © SADIK YAYLA³

¹Department of Medical Services and Techniques, Faculty of Ataturk Health Services Vocational School, Dicle University, Diyarbakır, 21280, Türkiye

²Department of Laboratory Animals, Faculty of Veterinary Medicine, Dicle University, Diyarbakır, 21280, Türkiye

³Department of Surgery, Faculty of Veterinary Medicine, Dicle University, Diyarbakır, 21280, Türkiye

Received 16.03.2026

Accepted 06.05.2026

Karakoç M., Baksi N., Karakoç Z., Yayla S.

Use of transcutaneous nerve stimulation, therapeutic ultrasound and low-level laser therapy methods in rats with experimental urinary incontinence

Summary

Stress urinary incontinence, defined as involuntary urine leakage during activities that increase intra-abdominal pressure, such as physical exertion, sneezing, or coughing, is a significant health problem that negatively impacts quality of life. Physiotherapy is one of the conservative treatments, and particularly noteworthy among the increasingly popular physiotherapy methods in the veterinary field are transcutaneous electrical nerve stimulation (TENS), therapeutic ultrasound (TU), and low-level laser therapy (LLLT). These are used alone or in combination. In this study, urinary incontinence was experimentally induced in a total of 28 female Sprague-Dawley rats, and a treatment plan consisting of a combination of TENS, TU, and LLLT was implemented. At the end of treatment, samples of bladder and pelvic floor muscle (PFM) tissues were taken. The findings of this study show that the combined application of TENS, TU and LLLT for treating urinary incontinence in rats contributes to the development of pelvic floor muscles. Therefore, TENS, TU, and LLLT may also be used for treating urinary incontinence by strengthening PFMs.

Keywords: incontinence, laser therapy, rat, transcutaneous electrical nerve stimulation, therapeutic ultrasound

Stress urinary incontinence (SUI) is defined as the involuntary leakage of urine during activities that increase intra-abdominal pressure, such as coughing, sneezing, or physical exertion (1). It represents a significant health concern, as it can substantially impair the quality of life, compromise personal hygiene, and disrupt social interactions (1, 4). Epidemiological studies indicate that SUI is more prevalent among women than men, with reported prevalence rates of 24.8% in the United States and 57.7% in Iran (17). Globally, approximately 420 million individuals – including 300 million women and 120 million men – were estimated to be affected by SUI in 2018 (1). Beyond its physical manifestations, SUI has profound psychosocial consequences: roughly 25% of affected individuals experience significant impairments in social functioning, mental health, occupational performance, physical activity, and sexual life (20). Feelings of shame,

anxiety, fear of leakage, and unpleasant odor often lead to social withdrawal (10, 15), while the frequent need to access the toilet increases the risk of falls and related injuries (5, 14). Collectively, these findings underscore that SUI is a multifaceted condition with physical, psychological, and social dimensions that together impose a substantial burden on affected individuals.

The etiology of urinary incontinence is multifactorial and involves primarily dysfunctions of the bladder and pelvic floor muscles (PFM) (3), connective tissue apparatus (9), as well as endopelvic fascia and/or neural connective tissue (8). The risk of urinary incontinence increases with age (19), but it can occur even in young women after their first delivery (2).

The development of UI is influenced by several risk factors, including predisposing factors (e.g., genetics and sex of the patient), factors related to damage to the urinary continence mechanism (e.g., abdominal

surgery, multiple births), and precipitating factors (e.g., overweight/obesity, menopause). Patients with mild-to-moderate SUI are generally advised to undergo conservative or noninvasive treatments before considering more invasive options, as these measures may lead to significant improvement (21). The goal of noninvasive interventions is to increase PFM function (6).

While a range of surgical and conservative approaches exist for the treatment of SUI, physiotherapy is widely recognized as a primary conservative intervention. Physiotherapy methods, such as massage, hydrotherapy, Transcutaneous Nerve Stimulation (TENS), Therapeutic Ultrasound (TU), and Low-Level Laser Therapy (LLLT) (12, 16), are becoming increasingly widespread in veterinary medicine, either individually or in combination (18, 22).

Therefore, creating a model of urinary incontinence in experimental animals is important both as an alternative model for human health and in terms of clinical outcomes. Furthermore, even though the etiopathogenesis differs, clinical problems related to urinary incontinence or detrusor muscle paralysis occupy an important place in small animal practice.

Although the etiology of UI is attributed to the urinary bladder muscle, ligament, pelvic muscles, and neurological causes, the use of these three physical therapy methods in this field is not sufficiently known. Therefore, this study aimed to evaluate the therapeutic efficacy of TENS, TU, and LLLT in an experimentally induced urinary incontinence model.

Material and methods

Ethics statement. All experimental procedures were conducted in accordance with the regulations of the Local Ethics Committee on Animal Experiments at Dicle University Health Sciences Application and Research Center. (Protocol no: 2024–23).

Animals and housing conditions. The experiments were conducted on 28 female Sprague Dawley rats (*Rattus nor-*

vegicus), obtained from the Medical Sciences Application and Research Center of Dicle University. The animals, aged 4 months and weighing between 272 and 352 g (Dikomsan, Jcs-a), were housed in a standard controlled environment ($22 \pm 1^\circ\text{C}$, 40-70% humidity, 12:12 h light/dark cycle from 8:00 am to 8:00 pm, 10 air changes per hour, noise level ≤ 75 dB, and light intensity ≤ 200 lux during the light phase). Throughout the 14-day experimental period, the rats had free access to standard chow and water.

Experimental procedure. Experimental animals were randomly divided into four groups ($n = 7$ per group): control, sham, and two different experimental groups. Experimental UI procedures followed a method described by Lin et al., (13). Accordingly, all rats were anesthetized with a combination of ketamine (80 mg/kg; Keta-Control®) and xylazine (8 mg/kg; Rompun®) intraperitoneally. While the rats were in the supine position, the bladder was emptied using a 1.0 mm urinary catheter placed in the urethra. Then, 1-2 drops of saline solution colored with methylene blue were instilled into the bladder to facilitate the detection of urine leakage. Pepper powder purchased from a local market was placed in both nostrils. In addition, a drop of saline solution was applied to each nostril to trigger sneezing. When the rat sneezed, the urethral tract was monitored for urine leakage. After bladder emptying, a 3.5 mL 8F Foley catheter was inserted into the vagina and secured to the skin with a single suture (Fig. 1). The Foley balloon was inflated with water and then held in place for 4 hours. After this procedure, the balloon was deflated and carefully removed. This ensured that urinary incontinence developed due to the stress on the bladder muscles, urethra, ligaments, and connective tissues caused by keeping the balloon inflated.

Physical therapy. The therapy consisted of a combination of TENS, TU, and LLLT (Fig. 2) (Intellect Vet Model 2756, DJ, LLC, ABD). TENS was applied in a premodulated waveform, continuous cycle, at 80/150 Hz frequency, 1.3-1.5 mA, for 300 seconds. TU (Intellect Vet; 1 MHz, continuous mode, SATA intensity 1.5 W, Chattanooga Group Inc., Chattanooga, TN, USA) was applied in an interrupted mode for 300 seconds. For LLLT, a GaAs (gallium arsenide)

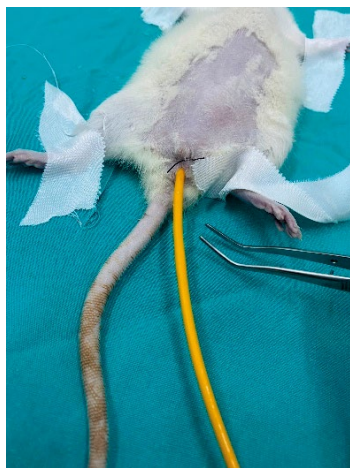


Fig. 1. After a 8F Foley catheter was inserted into the vagina, it was secured to the skin with a single suture and held in place

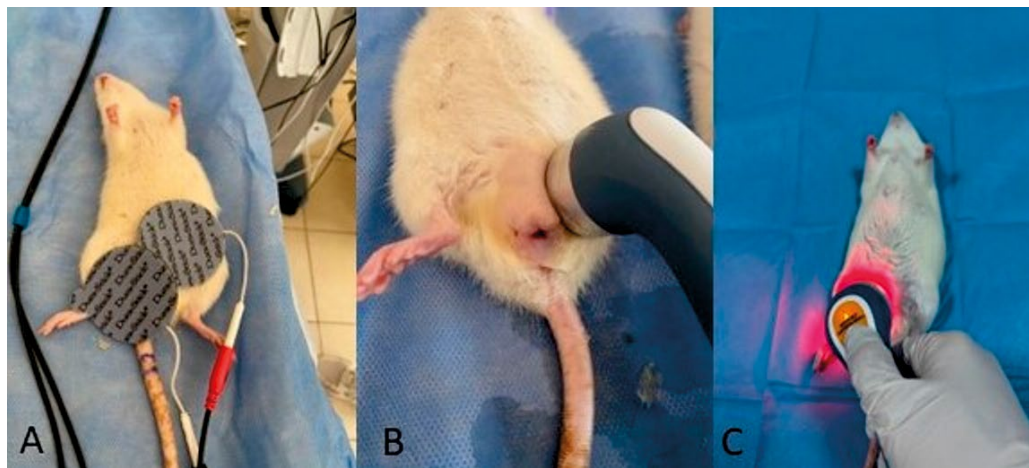


Fig. 2. Displays for TENS (A), TU (B), and LLLT (C); the treatment consisted of TENS, TU, and LLLT, in that order. TU was applied in a circular motion. A low-level laser was held at a right angle to the area

laser device (Lasermid 2200, Eme Phsio, Italy) was used at $\lambda = 905 \mu\text{m}$, 10,000 Hz, and 25 mW in a continuous mode, and the peak power was 25 W. A monodiode laser probe (MLA1/25) was applied from a close range by holding it perpendicular to the skin. Laser treatment was calculated according to the formula (power/beam area) X time = J/cm^2 , and $9 \text{ J}/\text{cm}^2$ was applied to the area through the skin for 60 seconds with regional scanning movements.

Description of experimental groups. The study was conducted in four groups.

Group 1 (Naive control): It consisted of standard rats, and no procedure was applied. Weight measurements were made at the beginning and end of the study to determine the basal values.

Group 2 (Sham group): In this group, only the procedure described above was performed, and no further treatment or physical therapy was administered.

Group 3 (Urinary Incontinence Treatment 1): After the experimental procedure was applied to the animals in this group, TENS, TU and LLLT were applied as physical therapy consistently once a day at the same time for seven days.

Group 4 (Urinary Incontinence Treatment 2): In this group, unlike the third group, the treatment was continued for 14 days.

At the end of the experimental protocol, the animals were euthanized by blood loss under general anesthesia (ketamine 80 mg/kg; Keta-Control® and xylazine (8 mg/kg; Rompun®). All procedures were performed in accordance with institutional and national guidelines regarding the care and use of laboratory animals. The incised bladder and pelvic floor muscles were removed, and routine histological tissue processing was performed.

Histopathological procedure. Samples of urinary bladder and pelvic floor muscle tissues obtained from all groups were fixed in 10% neutral formalin for 24 h. After rinsing under running water overnight, the tissue samples were blocked in paraffin after passing through 70%, 80%, 95%, and 100% alcohol series. From the prepared paraffin blocks, 5 μm thick serial sections were obtained with a rotary microtome (Leica RM-2125, Germany). The serial sections were stained according to a modified Crossman's Triple staining protocol. The stained slides were subsequently examined, assessed, and captured using a Nikon Eclipse 400 microscope with a DS-Ri digital camera and NIS Elements Imaging Software (version 3.10).

Muscle fiber atrophy, muscle volume, hemorrhagic areas, and collagen deposition were evaluated histopathologically and compared between groups. In morphometric evaluation, the diameters of the pelvic floor muscles were measured in the preparation. Diameter thicknesses were evaluated statistically and compared between groups.

Statistical analysis. Statistical analysis of the data used in this study was performed using the SPSS 27 statistical program. Parametric data were expressed as mean and standard deviation. Data normality was evaluated using the Shapiro-Wilk test. Normally distributed datasets were compared using ANOVA, while those that were not normally distributed were analyzed using the Kruskal-Wallis test. A P value ≤ 0.05 was considered statistically significant.

Results and discussion

Histopathological evaluation revealed that the submucosal layer in group 1 was prominent in the muscular layer. Muscles in this layer included normal circular and longitudinal smooth muscles and striated muscles. While no atrophy was observed between the fibers in this group, the smooth and striated muscles had a voluminous structure (Fig. 3). In group 2, atrophy in the pelvic floor muscles was visible macroscopically. Microscopically, evidence of atrophy with decreased fiber diameter in the tissues supported the macroscopic findings. It was determined that the striated muscle fibers in the muscular layer were thinned, and there were hemorrhagic foci and collagen accumulation between the fibers. Compared with the treatment groups, group 2 showed a more pronounced muscle atrophy (Fig. 3).

There was evidence of reduced muscle atrophy in the treatment groups (group 3 and group 4). The thickening and continuity of fiber diameter were notable findings in these groups, especially when compared

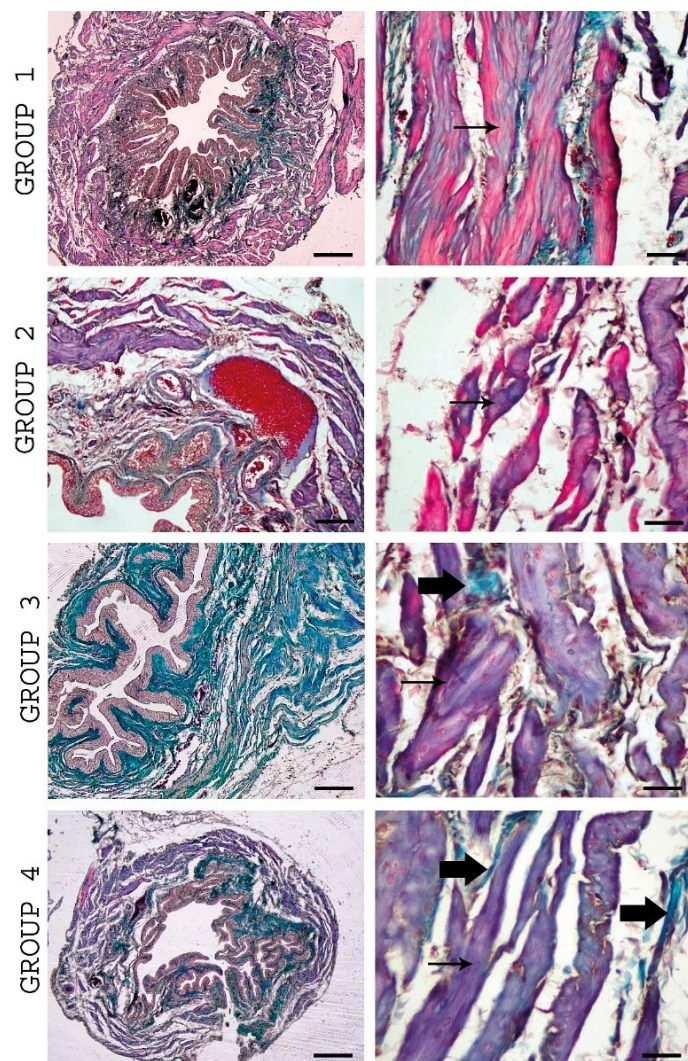


Fig. 3. Crossmon's triple staining in the urinary bladder in all groups. Thick arrow: collagen accumulation, thin arrow: muscle fiber atrophy. Group 1 has bulky striated muscle fibers. Group 2 shows a decrease in the striated muscle diameter

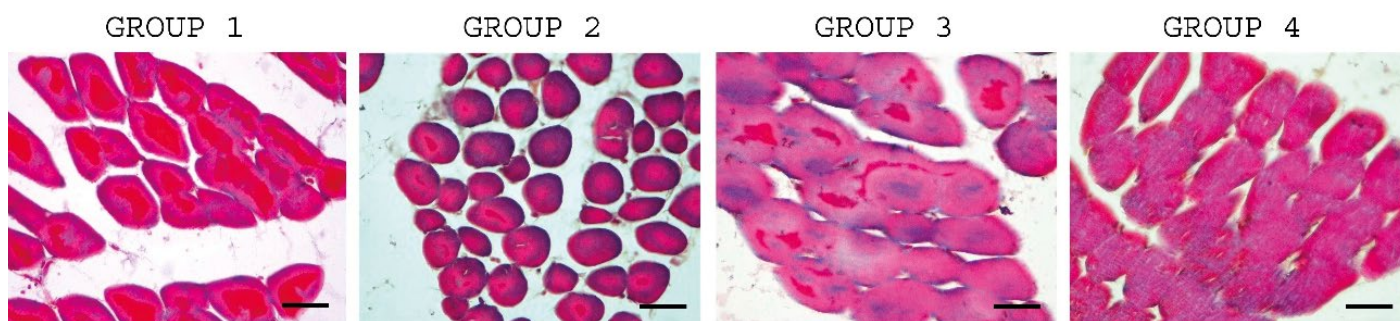


Fig. 4. Images of microfiber cross-sectional areas measured in the pelvic floor muscles. A noticeable decrease in muscle circumference was observed in group 2

Tab. 1. Comparison of myofiber cross-sectional area in the groups

	Group 1	Group 2	Group 3	Group 4
Myofiber cross sectional areas (μm^2)	122.85 \pm 45.90 ^a	50.28 \pm 13.73 ^b	285.14 \pm 78.79 ^c	450.42 \pm 33 ^d

Explanations: ^{a-d} Shows statistical difference in each row ($P < 0.05$).

with group 2 (Fig. 3). A reduction in hemorrhagic foci was also observed.

Morphometric examination revealed that the mean myofiber cross-sectional area was $122.87 \pm 45.90 \mu\text{m}^2$ in group 1, $50.28 \pm 13.73 \mu\text{m}^2$ in group 2, $285.14 \pm 78.79 \mu\text{m}^2$ in group 3, and $450.42 \pm 33 \mu\text{m}^2$ in group 4. The treatment groups exhibited a statistically significant increase in myofiber cross-sectional area compared with the control group ($P < 0.05$). In particular, group 3 and group 4 showed a significant increase relative to group 1, and group 4 demonstrated significantly higher values than both group 1 and group 3. These results suggest that TENS, TU, and LLLT effectively prevented pelvic floor muscle atrophy (Fig. 4, Tab. 1).

Although surgical and conservative interventions for urinary incontinence have been described, physiotherapy is one of the conservative treatments used. Pelvic floor muscle training (PFMT), biofeedback (BF) therapy, electrical stimulation (ES), and vaginal weights have been identified as physiotherapy options. Although these forms of treatment have already been adopted in clinical practice, the subject remains popular, and studies on the individual or combined use of new physiotherapy methods are ongoing (12). Massage, hydrotherapy, TENS, TU, and LLLT (23, 24), used individually or in combination, are increasingly common in veterinary medicine (25, 26). There have been reports of positive effects of TENS, TU, and LLLT, which are widely used especially in musculoskeletal, joint diseases and neurological injuries (7, 11).

This study evaluated histopathological changes in the pelvic floor muscles in a urinary incontinence model and the effects of TENS, TU, and LLLT on these changes. The combination of TENS, TU, and LLLT is used with synergistic effects, especially in musculoskeletal and joint diseases and neurological injuries (7, 16). However, its use in the treatment of urinary incontinence has not previously been described, which

highlights the importance of results obtained from the present study. In the control group, the prominence of the submucosal muscle layer and the voluminous and regular structure of striated and smooth muscles reflected the healthy anatomical integrity of the pelvic floor muscles. The absence of signs of atrophy indicates that the muscle tissue was stable under physiological conditions.

In the urinary incontinence group, macroscopic muscle atrophy was clearly observed, and these findings were supported microscopically by decreased fiber diameters, thinning of striated muscle fibers, foci of hemorrhage between fibers, and collagen deposition. This suggests that structural disruption of the pelvic floor muscles plays a central role in the pathophysiology of urinary incontinence. Collagen deposition and foci of hemorrhage indicated not only atrophy, but also inflammation and fibrotic changes.

Compared with these degenerative findings, significant improvements were observed in the treatment groups that received TENS, TU, and LLLT. In particular, the increase in fiber diameter, the maintenance of continuity in muscle tissue, and the reduction of hemorrhagic foci indicate that TENS, TU, and LLLT support tissue healing. It is also suggested in the literature that TENS facilitates motor unit participation by increasing neural activity, TU contributes to the healing process by stimulating microcirculation and cellular metabolism, whereas LLLT supports tissue repair with anti-inflammatory and regenerative effects (7, 11). In a systematic review on the effects of LLLT on skeletal muscle injuries, it was reported that laser therapy reduced the inflammatory process, modulated myogenic regulatory factors, and increased angiogenesis (12, 16). These effects may play a role in accelerating muscle regeneration.

In this study, according to morphometric evaluation, myofiber cross-sectional areas showed significant differences in all experimental groups. This finding clearly shows that TENS, TU, and LLLT prevent atro-

phy in the pelvic floor muscles. The more pronounced recovery in the pelvic floor muscles in the fourteen-day treatment group seems to confirm these mechanisms.

In contrast to the significant atrophy observed in the urinary incontinence group, the muscle structure in the treatment groups was more regular, atrophy was reduced, and connective tissue accumulation was limited. These results suggest that non-invasive therapies, such as TENS, TU, and LLLT, may be effective in preserving and repairing the pelvic floor musculature. In particular, muscle fiber diameter thickening and improvement in structural integrity are promising in terms of functional outcomes.

Clinically, the degree to which the bedding was wet was not considered important, because determining whether urination was controlled or not was extremely difficult for us in a study designed in this way. Therefore, the study indicators were based more on histopathological and morphometric analyses.

In conclusion, this study demonstrates that muscle atrophy and tissue degradation observed in the urinary incontinence model may be reversible with treatment protocols that combine TENS, TU, and LLLT. We believe that studies on this subject involving larger sample groups and functional evaluations will strengthen the role of preventive treatment options in clinical practice.

References

- Abrams P., Cardozo L., Fall M., Griffiths D., Rosier P., Ulmsten U., Van Kerrebroeck P., Victor A., Wein A.: The standardisation of terminology of lower urinary tract function: report from the Standardisation Sub-Committee of the International Continence Society. *Am. J. Obstet. Gynecol.* 2002, 187 (1), 116-126.
- Almoussa S., Bandin von Loon A.: The prevalence of urinary incontinence in nulliparous adolescent and middle-aged women and the associated risk factors: A systematic review. *Maturitas* 2018, 107, 78-83.
- Aoki Y., Brown H. W., Brubaker L., Cornu J. N., Daly J. O., Cartwright R.: Urinary incontinence in women. *Nat. Rev. Dis. Primers.* 2017, 3, 17042.
- Bardsley A.: An overview of urinary incontinence. *Br. J. Nurs.* 2016, 25 (18), 14-21.
- Boltero R., Urquhart D. M., Davis S. R., Bell R. J.: Prevalence and incidence of urinary incontinence in women: Review of the literature and investigation of methodological issues. *Int. J. Urol.* 2008, 15 (3), 230-234.
- Castro R. A., Arruda R. M., Zanetti M. R., Santos P. D., Sartori M. G., Girão M. J.: Single-blind, randomized, controlled trial of pelvic floor muscle training, electrical stimulation, vaginal cones, and no active treatment in the management of stress urinary incontinence. *Clinics (Sao Paulo)* 2008, 63, 465-447.
- Cheng K., Xia P., Lin Q., Shen S., Gao M., Ren S., Li X.: Effects of low-intensity pulsed ultrasound on integrin-FAK-PI3K/Akt mechanochemical transduction in rabbit osteoarthritis chondrocytes. *Ultrasound Med. Biol.* 2014, 40 (7), 1609-1618.
- DeLancey J., Gosling J., Creed K., Dixon J., Delmas V., Landon D., Norton P.: Gross anatomy and cell biology of the lower urinary tract, [in:] Abrams P., Cardozo L., Khoury S., Wein A. (eds.): *Incontinence*. Health Publication, Plymouth, UK, 2002.
- El-Sayed R. F., Morsy M. M., El-Mashed S. M., Abdel-Azim M. S.: Anatomy of the urethral supporting ligaments defined by dissection, histology, and MRI of female cadavers and MRI of healthy nulliparous women. *AJR Am. J. Roentgenol.* 2007, 189 (5), 1145-1157.
- Felde G., Ebbesen M. H., Hunskaar S.: Anxiety and depression associated with urinary incontinence: A 10-year follow-up study from the Norwegian HUNT study (EPINCONT). *Neurourol. Urodyn.* 2017, 36 (2), 322-328.
- Gölgeli Bedir A., Yanmaz L. E.: The effects of cream-based *Triticum vulgare* with and without therapeutic ultrasound on excisional wound healing in diabetic rats. *Cutan. Ocul. Toxicol.* 2023, 42 (2), 61-67.
- Hyytiäinen H. K., Bostrom A., Asplund K., Bergh A.: A systematic review of complementary and alternative veterinary medicine in sport and companion animals: electrotherapy. *Animals* 2023, 13 (1), 64.
- Lin A. S., Carrier S., Morgan D. M., Lue T. F.: Effect of simulated birth trauma on the urinary continence mechanism in the rat. *Urology* 1998, 52 (1), 143-151.
- Lukacz E. S., Santiago-Lastra Y., Albo M. E., Brubaker L.: Urinary incontinence in women: A review. *JAMA* 2017, 318 (16), 1592-1604.
- Melville J. L., Fan M. Y., Rau H., Nygaard I. E., Katon W. J.: Major depression and urinary incontinence in women: Temporal associations in an epidemiologic sample. *Am. J. Obstet. Gynecol.* 2009, 201 (5), 490.e1-7.
- Mille M. A., McClement J., Lauer S.: Physiotherapeutic strategies and their current evidence for canine osteoarthritis. *Vet. Sci.* 2023, 10 (1), 2.
- Mostafaei H., Sadeghi-Bazargani H., Hajebrahimi S., Salehi-Pourmehr H., Ghojzadeh M., Onur R., Chapple C.: Prevalence of female urinary incontinence in the developing world: a systematic review and meta-analysis. *Neurourol. Urodyn.* 2020, 39 (4), 1063-1086.
- Okur S., Okumuş Z.: Effects of low-level laser therapy and therapeutic ultrasound on Freund's complete adjuvant-induced knee arthritis model in rats. *Arch. Rheumatol.* 2023, 38 (1), 32-43.
- O'Reilly N., Nelson H. D., Conry J. M., Frost J., Gregory K. D., Kendig S. M., Conry J., Werner E. F.: Screening for urinary incontinence in women: A recommendation from the Women's Preventive Services Initiative. *Ann. Intern. Med.* 2018, 169, 320-328.
- Senra C., Pereira M. G.: Quality of life in women with urinary incontinence. *Rev. Assoc. Med. Bras.* 2015, 61 (2), 178-183.
- Syan R., Brucker B. M.: Guideline of guidelines: urinary incontinence. *BJU Int.* 2016, 117, 20-33.
- Yanmaz L. E., Ersoz U., Okur S., Apaydin Yildirim B., Comakli S., Sağlam Y. S., Dogan E., Karatas O., Turgut F., Okumuş Z.: The effect of low-level laser therapy on rat unicortical femoral defect. *Thai J. Vet. Med.* 2021, 51 (2), 277-284.

Corresponding author: Prof. Dr. Sadik Yayla; e-mail: sadik.yayla@dicle.edu.tr